

2013

3rd ISNVD Annual Meeting

23-25 February 2013 | Kraków | Poland



Dear Colleagues,

It is certainly a privilege and great pleasure to welcome you to the 3rd Annual Meeting of the International Society for Neurovascular Disease (ISNVD), which will be held in Kraków, Poland from 23-25 February 2013.

ISNVD has been founded to promote and scientifically coordinate research on a new and intriguing topic: vascular—particularly venous—background of a number of neurological disorders. For this purpose the Society encourages the exchange of information and ideas, and provides continuous education in this newly emerged area.

ISNVD provides a forum for the wide range of medical specialists: basic scientists, vascular surgeons and angiologists, neurologists and neurosurgeons, interventional radiologists, neuroradiologists, physicists, vascular technologists and others.

The conference will be held in the beautiful former capital of Poland, under the honorary patronage of the Mayor of the City of Kraków. The venue is the 4 star Park Inn by Radisson Kraków

The meeting will start with didactic sessions on: transcranial Doppler assessment of intracranial veins, extracranial Doppler screening of CCSVI, evaluation of MR venography of cerebral, jugular and azygous veins, endovascular treatment for CCSVI (the use of IVUS, management of atypical cases, redo procedures, etc.) and organization of acute stroke service.

This year's conference will be special in that we include in the program also sessions dedicated to the management of acute stroke. Then, there will be sessions on ultrasonographic and magnetic resonance diagnostics of venous insufficiency of the brain and spinal cord, on reports on clinical trials on the treatment for CCSVI, and on evidence of venous disorders in the settings of non-MS neurological disorders. A very important part of the scientific program will be represented by free paper and poster sessions. We expect a friendly discussion on those new data.

Since the venue is situated in the heart of the city centre, within walking distance of famous attractions, like the historic Wawel Castle and the Jewish district of Kazimierz, before or after the meeting it will be possible to enjoy a visit to all spectacular monuments of the city.

I look forward to welcome you to this high quality event and to exciting Royal Capital City of Kraków.

Yours sincerely,
Marian Simka MD PhD



President of the ISNVD

POSITIONAL VENOUS MR ANGIOGRAPHY OF THE CEREBRAL VENOUS BLOOD OUTFLOW SYSTEM

Niggemann P, MD

Introduction:

Chronic cerebrospinal venous insufficiency has been proposed as a cause for the manifestation or progression of multiple sclerosis. Its diagnosis bases on the comparison of duplex ultrasound findings acquired in supine and erect position. Duplex ultrasound however is an operator dependant modality and the reproducibility and relevance of the reported duplex ultrasound findings are discussed controversially.

The present work shows the use of positional venous MR angiography for the depiction of the cerebral venous blood outflow system (CVBOS) in healthy volunteers.

Methods:

At first a flow sensitive sequence in axial orientation acquired on the FONAR Upright MRT in sitting and supine position was evaluated in five healthy volunteers in regards to positional variation of the CVBOS. The findings were compared with T2 weighted images for exact positional anatomical correlation. In a second step a 2D TOF sequence, allowing 3D reformations of the CVBOS was established and evaluated in 15 healthy volunteers in regards to image quality and interindividual variance of the CVBOS. The extended of venous strictures and their positional behaviour was analysed.

Results:

Using the flow sensitive sequence it was possible to acquired images allowing the differentiation of vessels responsible for the cerebral venous blood outflow in supine and sitting position. The main outflow route was via the internal jugular vein (IJV) in supine and via a network of different vessels, mainly the vertebral plexus, in erect position. Imaging of the CVBOS using the 2D TOF sequence was possible in all volunteers despite a scan time of 21:45 min. The image quality was good for the cervical part of the CVBOS, however reduced for the thoracic part of the CVBOS because of motion artefacts. Half of the volunteers had strictures of the IJV only visible in supine position.

Conclusion:

Positional venous MR angiography is technically feasible and allows operator independent evaluation of the CVBOS.

HEMODYNAMICS AND TREATMENT RESPONSE IN VEIN STENOSIS: LESSONS FROM ILIAC STENT EXPERIENCE.

Seshadri Raju MDFACS

The Rane Center, USA

The largest clinical experiences with venous stenosis, to date, pertain to those found in the iliac-caval-femoral segments. This region has some unique clinical-pathological features. Nevertheless, the obstructive lesions are likely to share features common to all venous stenoses. The lessons learnt in treating these obstructive lesions may therefore have general validity. Four areas of possible general applicability will be illustrated:

1. Hemodynamics: Criteria developed for grading arterial stenoses are often inappropriately used for venous stenoses. While downstream flow is the 'critical' element in arterial stenoses, upstream pressure (back pressure) is the critical element in venous stenoses. Studies in experimental models suggest that clinical thresholds are likely lower in venous stenoses. While the stenotic element is the dominant factor in determining 'criticality' in arterial stenoses, more confounding factors are operational in venous stenoses. Extramural pressure exerted on the venous conduit when transiting through pressurized (positive or negative) chambers such as abdomen (positive) influence criticality of the stenoses as does outflow (atrial) pressure.
2. Epidemiology: Venous stenoses are widely prevalent in the general population in silent form. A fraction become symptomatic when secondary insults are superimposed. The venous stenoses function in a "permissive" fashion. The incidence of the lesion in symptomatic patients therefore will be very high similar to the incidence of patent foramen ovale (a well-known permissive lesion) in patients with paradoxical embolus. Permissive lesions are ubiquitous in human pathology. Examples include obesity and diabetes, acid reflux and asthma, ureteral reflux and pyelonephritis to mention just a few examples. A general principle is to treat the permissive lesion first in symptomatic patients which is often curative; specific address of secondary trigger events will be required less frequently.
3. Treatment: POBA (Plain old angioplasty) is uniformly ineffective in iliac vein stenosis due to the strong fibrous morphology. This is well documented with careful studies with IVUS planimetry. Limited experience with subclavian stenoses where the stenoses are associated with valve cusp abnormalities also indicate the inefficacy of POBA.
4. Selection of patients: Best results with venous stenting of iliac vein stenoses are seen in patients with early stages of the disease without end organ damage. Historically, a major difficulty in establishing efficacy of new therapeutic regimens is the fact that only advanced cases with end organ damage ("when all else have failed") will be referred for novel treatments.

CCSVI SESSION 1 – CURRENT STATUS OF RESEARCH

CHRONIC CEREBROSPINAL VENOUS INSUFFICIENCY (CCSVI) AT ECTRIMS 2012

Robert Zivadinov, MD, PhD, FAAN

Buffalo Neuroimaging Analysis Center, Department of Neurology, University at Buffalo, State University of New York, Buffalo, NY, USA

A newly proposed vascular condition, identified as Chronic Cerebrospinal Venous Insufficiency (CCSVI), has triggered great interest and debate highlighting the need for a better understanding of the role of extra-cranial venous anomalies and developmental variants. CCSVI was described as a vascular condition, characterized by anomalies of the main extra-cranial cerebrospinal venous routes, mainly in internal jugular veins (IJVs) and azygous vein that interfere with normal venous outflow from the brain to the periphery, being specifically associated with multiple sclerosis (MS). CCSVI implies a pathological condition the diagnosis of which is mainly based on color Doppler sonography of the extra (neck) - and intra-cranial veins using five venous hemodynamic criteria (with cutoff of ≥ 2 positive criteria used for a diagnosis of CCSVI).

The reliability of using Doppler sonography for the diagnosis of CCSVI is controversial, although consensus guidelines and standardized protocols are beginning to emerge. Use of other noninvasive imaging techniques like magnetic resonance venography and phase-contrast imaging are gaining increasing interest as an alternative diagnostic approach for screening and investigation of extra-cranial venous system anomalies, indicative of CCSVI. At this time there is a lack of standard protocols or established guidelines for an optimal diagnostic assessment for the diagnosis of CCSVI by using catheter venography. The use of intravascular ultrasound, as a novel diagnostic tool for confirming the presence and severity of CCSVI recently gained attention. Because each of these non-invasive and invasive imaging modalities has its own advantages and disadvantages, only a multimodal imaging approach will be ultimately the right choice for screening, diagnostic and monitoring purposes of CCSVI. None of the subsequent studies reproduced the originally reported prevalence of CCSVI, regardless of which diagnostic imaging method was used. Moreover, increased CCSVI prevalence has been found in a substantial number of healthy controls and patients with other neurologic diseases. The binary variable construction of the CCSVI diagnosis (yes/no) is probably the major reason for the inconsistencies reported, since the reported prevalence's of CCSVI between different studies range from 0-100%.

CCSVI provoked great controversy and debate in the MS community, primarily because of the postulated therapeutic effect of venous insufficiency correction using endovascular procedures. The safety and efficacy of endovascular treatment for CCSVI has not been proven in randomized, controlled or blinded trials. In addition, because patients with other neurologic diseases and healthy individuals may present with CCSVI, one may question whether endovascular treatment for CCSVI is necessary. We will present highlights from 2012 research presented at the European Committee for Treatment and Research in Multiple Sclerosis (ECTRIMS).

CCSVI Session 3 - CT and MRI

MULTIMODAL DIAGNOSTIC COMPARISONS OF 2 INVASIVE AND 3 NON-INVASIVE TECHNIQUES IN THE PROSPECTIVE RANDOMIZED ENDOVASCULAR TREATMENT IN MULTIPLE SCLEROSIS (PREMISE) STUDY

Robert Zivadinov, MD, PhD, FAAN

Buffalo Neuroimaging Analysis Center, Department of Neurology, University at Buffalo, State University of New York, Buffalo, NY, USA

The extra-cranial venous system is complex and variable. In the last decade, it has been repeatedly shown that the presence and severity of jugular vein reflux is associated with a number of central nervous system (CNS) disorders. A newly proposed vascular condition, named chronic cerebrospinal venous insufficiency (CCSVI), has triggered intense interest in better understanding the role of extra-cranial venous anomalies and developmental variants. Their association to intra-cranial CNS pathology, especially in patients with multiple sclerosis, is poorly understood at this time. The use of noninvasive diagnostic imaging techniques for the diagnosis of CCSVI such as Doppler sonography remains controversial; however, consensus guidelines and standardized protocols are emerging. The use of magnetic resonance venography and phase-contrast imaging is gaining an increasing interest as an alternative noninvasive diagnostic approach for the investigation of the extra-cranial venous system.

There is no established invasive diagnostic imaging modality that can serve as a "gold standard" for the detection of these venous anomalies/developmental variants at this time. The use of catheter venography and intravascular ultrasound are becoming important diagnostic tools for confirming the presence and severity of these venous anomalies/developmental variants in the internal jugular and azygous veins. Each of these noninvasive and invasive imaging modalities has its own advantages and disadvantages. Most likely, a multimodal imaging approach will ultimately be the most comprehensive means for screening, diagnostic as well as monitoring purposes. We will present multimodal diagnostic comparisons of 2 invasive and 3 non-invasive techniques used in the Prospective Randomized Endovascular Treatment in Multiple Sclerosis (PREMiSe) study. Further research is needed to determine the spectrum of these extra-cranial venous anomalies/developmental variants and to compare the imaging findings with pathological examinations. The ability to define and reliably detect noninvasively extra-cranial venous anomalies/developmental variants is an essential step toward establishing their incidence and prevalence. The proposed role for these anomalies in causing significant hemodynamic consequences for the intra-cranial venous drainage remains unproven. That being said, hemodynamic effects of these lesions on the extra-cranial venous system, need to be rigorously investigated, particularly in regards to their potential role in aging and CNS disorders.

VENOUS DISORDERS IN NON-MS NEUROLOGIC PATHOLOGIES

CHRONIC CEREBROSPINAL VENOUS INSUFFICIENCY (CCSVI) IN PEDIATRIC MULTIPLE SCLEROSIS AND OTHER NEUROLOGIC DISORDERS

Robert Zivadinov, MD, PhD, FAAN

Buffalo Neuroimaging Analysis Center, Department of Neurology, University at Buffalo, State University of New York, Buffalo, NY, USA

Background: Chronic cerebrospinal venous insufficiency (CCSVI) was recently described in patients with multiple sclerosis (MS). We reported that prevalence of CCSVI was 42.3% in a limited sample of 26 patients with other neurologic diseases (OND) and 50% in a limited sample of 10 pediatric MS patients.

Objectives: To determine prevalence of CCSVI in patients with pediatric and adult MS, patients with other pediatric and adult OND and age- and sex-matched healthy controls (HC), using specific proposed echo-color Doppler (ECD) criteria.

Methods: Transcranial and extracranial ECD exams were carried out prospectively in 78 adult OND patients and 234 adult HC (1:3 matching) and in 23 pediatric MS patients, 10 pediatric OND patients and 20 pediatric HC. HC group included genetically related and genetically unrelated subjects. Exclusion criteria were: pre-existing medical conditions known to be associated with brain pathology (e.g., cerebrovascular disease, positive history of alcohol abuse, etc.), history of cerebral congenital vascular malformations (Klippel-Trenaunay, Parkes-Weber, Servelle-Martorell, Budd-Chiari, syndromes) and pregnancy. The ECD evaluators were blinded to the subjects' status. A subject was considered CCSVI positive if ≥ 2 venous hemodynamic (VH) criteria were fulfilled. We also took into account subjects who presented ≥ 1 VH criteria, as well as subjects who presented with ≥ 1 or ≥ 2 extra-cranial VH criteria.

Results: . Prevalence was 53.9% in adult OND patients compared to 29.9% in adult HC ($p < 0.001$). CCSVI prevalence was 43.5% in pediatric MS, 40% in pediatric OND patients compared to 30% in pediatric HC ($p = 0.537$). In adult OND group, no significant differences were found in CCSVI prevalence between different OND subgroups: 58.3% in neuromuscular, 56% in neuroautoimmune, 53.3% in neurodegenerative and 45.5% in neurovascular ($p = 0.962$). When subjects who presented with ≥ 1 VH criteria were taken into account in adult population, the sensitivity was 79.5%, specificity was 34.2%, OR 2.01 (1.09-3.71), $p = 0.23$. When subjects who presented ≥ 1 or ≥ 1 extra-cranial VH criteria were taken into account in adult population, no significant differences between OND patients and HC were found.

Conclusions: Our findings are consistent with an increased prevalence of CCSVI in adult OND patients but with modest sensitivity/specificity. Similar prevalence of CCSVI among different adult OND subgroups, comparable to that seen in MS, points against CCSVI having a primary causative role in the development of OND or MS. No significant differences were seen for the extra-cranial VH criteria between adult OND patients and HC, suggesting that higher prevalence of CCSVI in OND patients is driven by an increased frequency of intra-cranial VH criterion 2 (deep cerebral vein reflux). Our findings showed similar prevalence of CCSVI between pediatric MS and OND patients, and HC. These findings point against CCSVI having a primary causative role in the development of MS or OND.

CEREBRAL VENOUS RETURN AND CHRONIC NEUROLOGICAL CONDITIONS

J.Valk MD, PhD

N. van Vucht, MD

Ph. Pevenage, MD

VU academic medical center

MRI center, Amsterdam

Introduction:

This presentation is part of our continuing prospective study of patients with chronic intractable headache, and, if present, concurrent symptoms and signs, such as vertigo, dizziness, pulsatile and non-pulsatile tinnitus, and visual obscuration. In this context attention will be given to the close relationship between venous pressure and CSF pressure, in a number of our patients with the triad of MR signs of ("Idiopathic") Intracranial Hypertension, in fact CSF hypertension.

Material and Methods:

All patients with complaints as abovementioned (headache subjective > 7 on a scale of 0-10, and medication effect < 3 on a scale 0-5), male and female, older than 16 years, were included. MR studies were performed on a Siemens 1.5 T Symphony, using a standard head and neck coil combination and including transverse Proton Density, T2-weighted and Flair images, coronal T2-weighted images including the optic nerves, Susceptibility Weighted Images and MRA.

MR venography was performed as Time of Flight (TOF) sequence, covering head and neck in a 2D-oblique sagittal plane, with maximum intensity projection (MIP) to visualize the veins. Application of IV contrast was done in cases where an impression of collateral circulation was considered to be informative, of importance in follow-up studies. To only use contrast enhanced MRV or CT venography; always depending on contrast, may obscure segmental thrombosis.

To confirm a diagnosis and always in patients with tinnitus, 3D-phasecontrast angiography (Velocity Encoding, VENC 20- or 30- ml/sec.) was performed, showing both arteries and veins on the MIP reconstructions.

In this presentation we will focus on one group with chronic headache, uni- or bilateral pulsatile or non-pulsatile tinnitus, and a persistent occipital sinus (POS).

Results:

There is a considerable variation of POS and knowledge of the anatomy of the venous structures in the posterior fossa is mandatory for posterior fossa surgery. Some of these variations seem more thrombogenic than others and quite a few suggest an explanation for tinnitus, important when all other causes have been excluded. The latter applies in particular when there is "loop" formation: a circuit consisting of the POS (uni- or bilateral), transverse and sigmoid sinus and jugular bulb). In some cases this result in sufficient increase in venous-CSF pressure to produce the MR criteria for Intracranial Hypertension, often combined with either pulsatile or non-pulsatile tinnitus. The findings led to a decision tree for cases with segmental thrombosis without and with MRI criteria for raised intracranial CSF pressure.

Conclusions:

MR venography should be part of the MRI protocol for patients with the described complaints.

The group with signs of raised cerebrospinal pressure ("benign" intracranial hypertension, pseudotumor cerebri) should be considered for endovascular treatment, when obstruction of veins can be shown on MRV.

In patients without these signs, but on MRV indication of partial, segmental thrombosis, reducing all thrombogenic factors, obtain an impression of the collateral circulation, and eventually apply anticoagulant medication.

References:

1. Valk J, Van Vucht NE, Pevenage PH. MR Venographic Patterns in Chronic Intractable Headache. *The Neuroradiology Journal* 2011. February; 24:13-19 .
2. Puffer RC, Mustafa W, Lanzino Gu. Venous stenting for idiopathic intracranial hypertension: a review of the literature. *J Neurointervent Surg*, 2012, 0: 1-4
3. Leach JL, Fortuna RB, Jones BV, Gaskill-Shiple MF. Imaging of Cerebral Venous Thrombosis: Current Techniques, Spectrum of Findings, and Diagnostic Pitfalls. *Radio Graphics* 2006; 26: S19–S43.
4. Kobayashi K, Suzuki M, Ueda F, et al; Anatomical study of the occipital sinus using CE- MR venography. *Neuroradiology* 2006; 48: 373–379.

CEREBRAL CIRCULATION TIME IN MULTIPLE SCLEROSIS PATIENTS

Marcello Mancini

Institute of Biostructure and Bioimaging, Italian National Research Council (CNR), Naples, Italy

Background Recent newly developed ultrasound techniques extend our ability to study the cerebral hemodynamics in patients with neurological disease beyond the conventional blood flow velocity analysis. Different ultrasound methods are currently under investigation that either qualitatively or quantitatively describe brain perfusion. The most widely used technique is bolus kinetics. After applying a ultrasound contrast agent bolus, time intensity curves of the wash-in and wash-out phase of the bolus passage through the brain are registered by imaging at a set frame rate and analyzing the ultrasound intensity in a given region of interest. Based on the time intensity curves, different parameters can be extracted such as peak intensity, time to peak, mean transit time, and incremental time (Fig1). These parameters can be displayed in a tissue region of interest defined by the examiner. Studies based on histopathological techniques and on MR imaging demonstrate hypoxia-like brain tissue injury or thrombosis of small veins in patients with Multiple Sclerosis (MS). Applying dynamic susceptibility contrast Magnetic Resonance Imaging, cerebral mean transit time values were found to be significantly prolonged in MS patients. We present the application of contrast enhanced ultrasound (CEUS) to assess global cerebral circulation time (CCT) in patients with multiple sclerosis (MS). The method is based on the assumption that the time required by an ultrasound contrast agent to pass from the cerebral arteries to the veins should be prolonged in patients with vessel disorders.

Methods We performed CEUS in 82 patients with MS, and 37 controls. The clinical diagnosis was established by neurological evaluation and neuroimaging findings. Impairment was assessed by the EDSS Scale. Cerebral Circulation Time was defined as the time difference of ultrasound contrast bolus arrival between the carotid artery and internal jugular vein.

Results The MS patients were comparable to control subjects for age, sex, systolic and diastolic blood pressure and heart rate. The artery arrival time was similar in MS group and controls. The longest and average Cerebral Circulation Times (CCTL,CCTM) were substantially prolonged in patients with MS compared with controls [CCTL MS patients: median (range) 6.5 sec. (3.3-29.2); controls 5.2 (2.57-7.63; $p<0,0001$. CCTM MS patients: median (range) 5.8 sec. (2.6-17.5); controls 4.7 (2.5-7.1); $p<0,0001$] No correlation was found between Cerebral Circulation Times and duration of disease or age in both group of patients and controls. Moreover, the degree of circulatory delay was not correlated with the level of disability (EDSS score).

Conclusions Compared with the healthy control group, MS patients showed a significant prolongation of CCT. Our results suggest that a microvascular or venous outflow impairment could be associated with MS. The CEUS measurement of CCT may be useful tool to disclose cerebral microcirculatory dysfunction in MS patients.

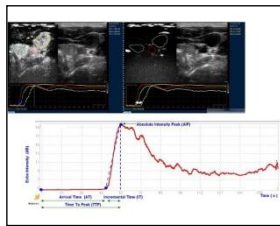
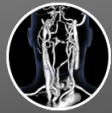

Fig. 1 The time-intensity curve analysis displays the acoustic intensity (in dB) during acquisition time in three different region of interest: the carotid artery, thyroid parenchyma without artery/vein, Internal Jugular Vein. The wash-in curves were analysed and three parameters were measured for the ROI: Arrival Time, Time To Peak and Absolute Intensity Peak.

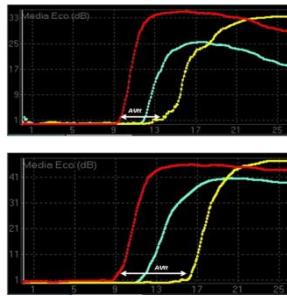


Fig.2 The CCT_L in a MS patient (bottom) and in a control subject (top). The difference was evident (CCT_L in control subject was 3.3 s, in MS patient was 6.9s.. The red lined curve depicts the arterial signal, the green lined curve represents tissue signal and yellow lined curve represents the venous signal.

CHRONIC CEREBROSPINAL VENOUS INSUFFICIENCY IS UNLIKELY TO BE A DIRECT TRIGGER OF MULTIPLE SCLEROSIS

Marian Simka, MD, PhD, Maciej Zaniewski, MD, PhD, Tomasz Ludyga, MD, PhD, Paweł Łatacz, MD, PhD, Marek Kazibudzki, MD, PhD and Eugeniusz Majewski, MD, PhD

EuroMedic Medical Center, ul. Kościuszki 92, Katowice, Katowice, Poland

ABSTRACT:

Background

Chronic cerebrospinal venous insufficiency, vascular pathology comprising stenosed veins draining the central nervous system, can accompany multiple sclerosis and is suspected to be involved in its pathogenesis.

Objective

This study was aimed at exploring a potential role for chronic cerebrospinal venous insufficiency in triggering multiple sclerosis. If it were venous abnormalities responsible for neurological pathology, one should expect a negative correlation, i.e. more severe vascular lesions in the patients with early onset of the disease.

Methods

Localization and degree of venous blockages in 350 multiple sclerosis patients were assessed using catheter venography. Statistical analysis comprised evaluation of the correlations between severity of venous lesions and patients' age at onset of the disease.

Results

We found weak, yet statistically significant, positive correlations between patients' age at onset of multiple sclerosis and accumulated and maximal scores of venous lesions. The patients, also those with duration of the disease not longer than 5 years, who had their first attack of multiple sclerosis at a younger age presented with less severe vascular lesions.

Conclusion

Positive correlations suggest that venous lesions are not a direct trigger of multiple sclerosis. There should be another factor that initiates pathological processes in the central nervous system.

CEREBRAL VENOUS OUTFLOW: A SONOGRAPHIC QUANTITATIVE EVALUATION

L. Monti MD, E. Menci MD, P. Piu MSC, S. Leonini MD, M. Bellini MD, A. Casasco^a MD, A. Cerase MD

Unit of Neuroimaging and Neurointervention, Department of Neurological and Sensorineural Sciences, Azienda Ospedaliera Universitaria Senese, "Santa Maria alle Scotte" General Hospital, Viale Bracci, 2 – 53100 Siena, Italy

Fax: +39-0577-586197; Tel: +39-0577-585049; e-mail: l.monti@ao-siena.toscana.it

^a Unit of Endovascular and Percutaneous Therapy, Clinica Nuestra Señora del Rosario, Madrid, Spain

Abstract

Background

Internal Jugular Veins (IJVs) are the principle outflow pathway for intracranial blood in clinostatism condition. In the seated position, IJVs collapse, while Vertebral Veins (VVs) increase the venous outflow and partially compensate the venous drainage. Spinal Epidural Veins are an additional drainage pathway in the seated position. Colour- Doppler-Sonography (CDS) examination is able to demonstrate IJVs and VVs outflow in different postural and respiratory conditions. The aim of this study was to evaluate CDS quantification of the cerebral venous outflow (CVF) in healthy subjects and patients with multiple sclerosis (MS).

Methodology/Principal Findings

In a group of 27 healthy adults (13 females and 14 males; mean age 37.8 ± 11.2 years), and 52 patients with MS (32 females and 20 males; mean age 42.6 ± 12.1 years), CVF has been measured in clinostatism and in the seated position as the sum of the flow in IJVs and VVs. The difference between CVF in clinostatism and CVF in the seated position (Δ CVF) has been correlated with patients' status (healthy or MS), and a number of clinical variables in MS patients. Statistical analysis was performed by Fisher's exact test, non-parametric Mann-Whitney U test, ANOVA Kruskal-Wallis test, and correntropy coefficient.

The value of Δ CVF was negative in 59.6% of patients with MS and positive in 96.3% of healthy subjects. Negative Δ CVF values were significantly associated with MS ($p < 0.0001$). There was no significant correlation with clinical variables.

Conclusions/Significance

Negative Δ CVF has demonstrated a pathologic condition in MS patients. In fact this hemodynamic alteration reflects an increased venous return in the seated position. In MS patients, a vascular dysregulation resulting from involvement of the autonomous nervous system may be supposed. Δ CVF value should be included in the quantitative CDS evaluation of the cerebral venous drainage, in order to identify cerebral venous return abnormalities.

CASE REPORT OF INTERNAL JUGULAR VEIN ENTRAPMENT IN A MULTIPLE SCLEROSIS PATIENT

Marian Simka, MD, PhD and Maciej Zaniewski, MD, PhD

EuroMedic Medical Center, ul. Kościuszki 92, Katowice, Katowice, Poland

ABSTRACT:

In this case report we describe multiple sclerosis patient presenting with compression of the internal jugular vein caused by aberrant omohyoid muscle. Previously this patient underwent balloon angioplasty of the same internal jugular vein. Ten months after this endovascular procedure Doppler sonography revealed totally collapsed middle part of the treated vein, with no outflow detected. Still, the vein widened and the flow was restored with the patient's mouth opened. Thus, the abnormality was likely to be caused by muscular compression. Surgical exploration confirmed that an atypical omohyoid muscle was squeezing the vein. Consequently, pathological muscle was transected. Sonographic control three weeks after surgical procedure revealed a decompressed vein with fully restored venous outflow. Although such a muscular compression can be successfully managed surgically, future research has to establish its clinical relevance.

CUTTING BALLOONS FOR THE TREATMENT OF OBSTRUCTIVE LESIONS IN THE INTERNAL JUGULAR VEINS: FEASIBILITY REPORT

Paweł Latacz, MD, PhD, Marian Simka, MD, PhD, Marek Kazibudzki, MD, PhD and Tomasz Ludyga, MD, PhD

EuroMedic Medical Center, ul. Kościuszki 92, Katowice, Katowice, Poland

ABSTRACT:

Aim

This technical report is aimed at the assessment of feasibility and safety of cutting-balloon angioplasty for the management of malformed internal jugular veins: the so-called chronic cerebrospinal venous insufficiency.

Methods

We used cutting balloons during 70 procedures in 65 multiple sclerosis patients presenting with strictures of the internal jugular veins, primarily at the level of jugular valves. These devices were used only in selected cases, following unsuccessful standard balloon angioplasty, and on condition that commercially available cutting balloons could be applied (currently they are maximally 8 mm in diameter).

Results

In all cases the perioperative course was uneventful. Short-term success rate was 89.6%. In four cases cutting-balloon angioplasty was unsuccessful and stents were implanted. Follow-up (routinely: 3-6 months after the procedure) has revealed that out of remaining 66 angioplasties 4 procedures failed: in two patients treated vein restenosed and stents were implanted, in the other patient successful redo cutting-balloon angioplasty was performed, while in one case treated segment of the internal jugular vein completely re-occluded and it was impossible to reopen the vein endovascularly.

Conclusion

Cutting balloons can be safely used for the management of stenosed internal jugular veins. These devices can replace the stents in majority of cases, especially if standard balloon angioplasty is insufficient to restore proper outflow. However, the use of cutting balloons in this particular venous territory is limited by the fact that currently only small diameter devices are commercially available. However, clinical efficacy of such procedures should be assessed by randomized trials.

EXPERIENCE IN 144 ENDOVASCULAR TREATMENT OF CCSVI IN MULTIPLE SCLEROSIS

A. Bruno, MD, D. De Lucia, MD, PhD, D. Mastrangelo, MD and B. Bernardo, MD

Division Vascular Surgery GEPOS –Telese (BN) ITALY, General Hospital at Second University of Naples ITALY, Vasculari Division, GeposVia Rima, Telesse, Benevento, Telesse, Italy, +30824949111

ABSTRACT:

Introduction

Multiple Sclerosis (MS) is an autoimmune disease characterized by multifocal areas of inflammation and demyelization within the central nervous system (CNS). The mechanism that trigger the disease remains elusive. However, recent findings may indicate that multiple sclerosis, at its source, could be a hemodynamic disorder. Endovascular treatment has been suggested for chronic cerebrospinal venous insufficiency (CCSVI).

Zamboni and co-workers found that MS patients exhibited significant stenoses in extracranial veins that drained the CNS (Zamboni et al., 2008).

Authors have twenty years experience in endovascular treatment of arterial and venous diseases and taking into consideration the recent discovery made by Prof. Zamboni regarding the presence of endoluminal malformations of the jugular and/or azygos veins in patients with MS, have extended their field of application to CCSVI.

Materials and Methods

Between February 2011 and July 2012, 144 endovascular procedures were performed in 110 patients affected by MS with at least two positive parameters for CCSVI.

Patients were selected according to the criteria developed by Prof. Zamboni using echoDoppler ultrasound method performed by My.Lab Vinco equipment. The patients had been diagnosed with the disease 1 to 34 years previously and all patients had functional deficits resulting from the MS. The following clinical outcome measures were used: annual relapse rate and Expanded Disability Status Scale (EDSS) score. The patients were not selected according to their type of MS.

All the patients were observed intensively (mean 8 hours) on the day of the endovascular treatment to monitor for possible complications (re-thrombosis, bleeding, shock, heart attack).

Standard endovascular technique was used, through a femoral percutaneous approach performing a single or multiple PTA of internal jugular vein and/or azygos vein. Patients was given intraoperatively a single dose of sodium heparin (5000 iu)

and were discharged the day after with prescription of high dosage LMW heparin (8000 iu sc twice/day/20 days followed by assumption of Mesoglycan at dosage of 100 mg/day for prolonged periods (12-24 months).

It was recommended a follow-up by neurological examination and ecocolorDoppler according to the protocol Zamboni be undertaken at intervals of 1, 3, 6, 9 and 12 months.

Results

We reported good results in about 55% of patients, immediately at discharge or at most one month later. In 25% of patients we observed a recurrence of clinical symptoms (mean interval: 3 months). Twenty percent had no benefits.

In only 2 cases (0.1%) was there a resurgence of the disease after 3 months which was treated with high-dose steroid therapy.

In our experience no major complications occurred; only two cases presented a minor complication (inguinal hematoma), which was quickly resolved without any further need for hospitalization. Thirty-four patients required a second treatment after 6 months because a clinical recurrence and a restenosis identified by US.

Thus, the localization of venous obstructions could significantly influence the clinical picture and prognosis of the disease.

Conclusion

We here report the results of the extended follow-up of patients included in a preliminary self-controlled program which evaluated the clinical effects of endovascular treatment for CCSVI in a cohort of relapsing-remitting (R-R) MS patients. Our findings have shown that there were venous abnormalities in patients with MS.

We believe that the endovascular treatment of CCSVI is safe, effective in almost 55% of patients and can be combined to drugs already being used. These good results must be considered, even if there is no unambiguous criterion of the relationship between treatment and benefit especially for long-term results.

Therefore, patients will need to be followed before and after treatment to objectively assess changes in flow and their effects in patients recovery after percutaneous transluminal angioplasty.

In addition to or instead of pharmacotherapy, surgical correction could be an option in some anatomical variants of pathological venous outflow.

The authors feel that a hemodynamic approach to the MS patients could open a new sphere of investigations and treatment of this debilitating neurologic disease.

COMPARISON OF INTRAVASCULAR ULTRASOUND (IVUS) TO GOLD STANDARD CATHETER VENOGRAPHY (CV) FOR DETECTION OF EXTRA-CRANIAL VENOUS ABNORMALITIES INDICATIVE OF CCSVI: RESULTS OF THE PREMISe (PROSPECTIVE RANDOMIZED ENDOVASCULAR THERAPY IN MULTIPLE SCLEROSIS) STUDY

Adnan H. Siddiqui, MD, PhD¹, Yuval Karmon, MD¹, Robert Zivadinov, MD, PhD², Bianca Weinstock-Guttman, MD², Karen Marr, RVT³, Vesela Valnarov, RVT³, Kresimir Dolic, MD³, Cheryl Kennedy, MPH³, Nelson Hopkins, MD¹, Elad I. Levy, MD¹

¹University of Buffalo Neurosurgery, Inc., 100 High Street, Suite #B-4, Buffalo, New York, Buffalo, USA

²Department of Neurology, The Jacobs Neurological Institute, State University of New York, 100 High St, Buffalo, NY, Buffalo, USA

³Buffalo Neuroimaging Analysis Center, State University of New York, Buffalo, NY, 100 High Street, Buffalo, NY, Buffalo, USA

ABSTRACT:

Purpose

To investigate prevalence of extra-cranial abnormalities in azygos (AZY) and internal jugular veins (IJVs) using catheter venography (CV) and intravascular ultrasound (IVUS).

Methods

This prospective study was approved by the Institutional Review Board and all participants gave their informed consent. Prospective Randomized Endovascular therapy in Multiple Sclerosis (PREMiSe) is an endovascular angioplasty study that enrolled 30 patients with relapsing MS who fulfilled ≥ 2 VH extra-cranial Doppler sonography (DS) criteria at screening. Phase I of the study included 10 patients and was planned to gain experience with using IVUS, whereas phase II enrolled 20 MS patients and further validated diagnostic assessments by using 2 invasive techniques (CV and IVUS). CV was considered abnormal when $\geq 50\%$ restriction of the lumen was detected. IVUS was considered abnormal when $\geq 50\%$ restriction of the lumen, or intraluminal defects were detected or reduced pulsatility was detected.

Results

No operative or postoperative complications, including vessel rupture, thrombosis, or side effects to the contrast media, were recorded. Venous abnormalities detected by IVUS were observed in 85% of the AZY veins, 50% of right IJVs and 83.3% of left IJVs, while CV showed stenosis of $\geq 50\%$ in 50% of AZY veins, 55% of right IJV and 72% of left IJV. The CV sensitivity for detecting IVUS abnormalities was 52.9%, 73.3% and 80% for the AZY, left IJV and right IJV, respectively.

Conclusions

IVUS assessment of AZY and IJVs showed higher rate of venous abnormalities compared to CV. IVUS provides diagnostic advantage over "gold standard" CV in detecting extra-cranial venous abnormalities indicative of CCSVI.

A HAEMODYNAMIC MODEL TO CALCULATE NON INVASIVELY THE BRAIN OUTFLOW THROUGH COLLATERAL VESSELS

Francesco Sisini, PhD*, Erica Menegatti, PhD, Angelo Taibi, PhD*, Anna Maria Malagoni, MD, Sandra Morovic, MD, Mauro Gambaccini, PhD*, Paolo Zamboni, MD

Vascular Diseases Center, University of Ferrara, 44100 Ferrara, Italy

*Department of Physics, University of Ferrara, 44100 Ferrara, Italy

ABSTRACT:

There is general agreement in considering the internal jugular veins (IJVs) the major route of cerebral outflow in the supine position, and the vertebral veins (VVs) as the major route of brain drainage in upright. The IJV is normally divided into 3 segments: the segment J3 or higher, which anatomically is located at the carotid bifurcation and the mandibular angle, the middle segment or J2, anatomically related to the ipsilateral thyroid lobe, and finally, the lower end or J1, corresponding to the confluence with the brachio cephalic vein trunk.

In a recent paper we have shown that the flow tends physiologically to grow in volume from J3 to J1, both in basal conditions and under standardized conditions of activation of the thoracic pump. The main question to be answered is why the IJV flow is increased from the skull to the chest. Our hypothesis is to take into consideration the possibility of re-entry of blood from jugular collaterals into the main trunk. Further more, the re-entry volume through collateral vessels might contain also blood of the brain and not only that directed to the inflow of face and neck soft tissue. In fact, there is a never assessed amount of blood flowing to the brain respectively via the carotid and vertebral arteries that is conveyed into the IJV more caudal with respect to the J3 position, through intra and extracranial anastomosis. We know the anatomical presence of intra and extra cranial connection but their physiological contribution to brain circulation is completely unknown. To this aim we have developed an haemodynamic lumped model (Fig. 1) which describes quantitatively the neck pathway of the cerebral venous return normalized respect to the arterial inflow measuring flow parameters by the means of established echo-colour Doppler (ECD) methodology. Finally, in the second phase of the research, we have performed preliminary measurements in normal subjects and in patients affected by Chronic Cerebrospinal venous insufficiency (CCSVI).

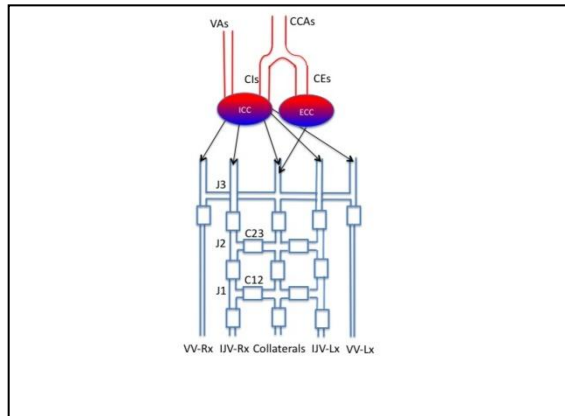


Fig 1 Lumped model of the haemodynamic of the neck pathway of the cerebral venous return. Red tubes represent in-flow vessel, blue tubes represent out-flow vessel, tube resistance is represented by hydraulic valve symbol.

CLINICAL ASSESSMENT OF PATHOPHYSIOLOGY IN NEUROVASCULAR DISEASES BASED ON QUANTITATIVE DCE-MRI

Laura Fanea, PhD, Georgeta Mihaela Rusu, RVT and Silviu Andrei Sfrangeu, MD

Cluj County Emergency Hospital, str. Clinicilor, nr. 3-5, Cluj-Napoca, Cluj, Cluj-Napoca, Romania

ABSTRACT:

Introduction

Neurovascular diseases represent a major health problem and the clinical imaging method of choice at the moment is magnetic resonance imaging (MRI). At present, in clinical MRI laboratories, most of the information is qualitative. Quantitative methods for the interpretation of MRI images, generally, and the neurovascular MRI images, particularly, are developed and evaluated for their clinical implementation in the future. Perfusion is among the most important quantitative methods for the evaluation of the neurovascular pathophysiology. There are three main perfusion methods with or without contrast agents that can be used in MRI. Dynamic contrast enhanced MRI (DCE-MRI) is the perfusion method with the highest signal-to-noise ratio and the most relevant clinically at the moment. Quantitative evaluation of the pathophysiology can be achieved using DCE-MRI methods and compartment modeling of the MRI data. In the present study a slow infusion DCE-MRI method using a three compartment model previously evaluated theoretically and then tested on the normal and hydrocephalic rat brain at 9.4 T was used to quantitatively analyze the brain perfusion of patients with neurovascular disease.

Materials and Methods

Patients with different neurovascular disease were selected for DCE-MRI at 1 T (GE, USA) pre- or post- surgery. The DCE-MRI brain data was collected before, during and post- infusion of the contrast agent using a slow infusion technique. The MultiHance (Bracco, Italy) contrast agent was injected (0.2 mg/kg GD-DTPA) at a rate of 5 ml/s using an automatic injector. A volume of 5 ml 0.9 % physiological saline was injected before and after the infusion of the contrast agent. Several MRI images were collected before, during and after the infusion of the contrast agent using a rapid 3D SPGR pulse sequence. The DCE-MRI data was then mathematically modeled using a 3-compartment modeling method recently described and tested on hydrocephalic rat brains at 9.4 T. This method allows the quantitative evaluation of the kinetics of ^1H spins in water molecules in two different pools to be quantitatively assessed in the relevant brain regions: blood, tissue (white and grey matter) and cerebrospinal fluid.

Results

The rate of the evacuation of the ^1H spins in water molecules with the relaxation time T_1 altered was indirectly assessed by the extraction of the K_{OUT} (1/s) values. An example of the arterial input function (AIF) generated for a patient with meningioma

post-surgery is presented in Figure 1 with red. The K_{OUT} value was extracted for this patient based on measurements performed on the MRI signal intensity in the sagittal sinus. These measurements at different time points are then used to build the AIF (Figure 1 in red) and to extract the K_{OUT} value expressed in 1/s. There is no visible sign of abnormalities in this patient in the brain tissue in the scanned region. So, according to a qualitative evaluation of the MRI images, there is no sign of disease in the brain tissue. However, the extremely large K_{TRANS} value extracted from the tissue curve built using the compartment modeling (Figure 1 in blue) suggests severe blood-to-brain barrier disruption and possible blood vessels inflammation.

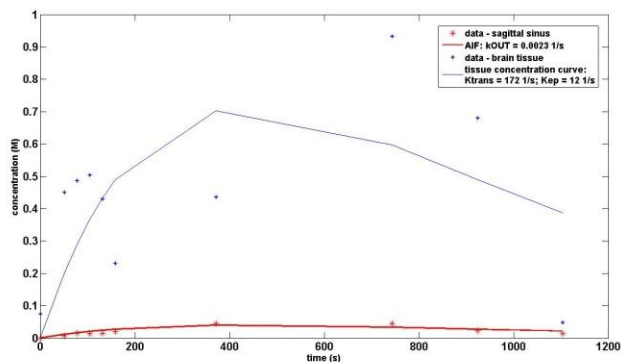


Figure 1 Arterial input function and tissue concentration curve from DCE-MRI data of the brain post-surgery of meningioma. The arterial input function was calculated from the sagittal sinus MRI data in a patient 3 months post surgery of meningioma. The tissue concentration curve was calculated in the brain tissue away from the location of the extracted tumor. The estimated transport rate estimated from the AIF is 0.0023 1/s, while that estimated from the tissue brain data are: $K_{TRANS} = 172$ 1/s and $K_{EP} = 12$ 1/s. The extremely elevated value of the K_{TRANS} in the brain tissue may be related to extremely rapid transport taking place at the blood to the extracellular space barrier in the brain tissue and may indicate severe blood-to-brain barrier disruption and blood vessel inflammation.

Conclusion

The quantitative evaluation of the DCE-MRI data using slow contrast agent infusion methods and compartment modeling can be used to quantitatively assess the kinetics of 1H spins in water molecules in two different pools in the main brain components: blood, tissue and cerebrospinal fluid. The transport rates of these spins in the compartments mathematically modeled may become helpful indicators of dynamic disturbances in different regions of the brain or in different compartments of a brain region. This quantitative information may become extremely important especially when the qualitative information provided suggests no sign of abnormalities. The quantitative evaluation of the dynamics in different brain regions and compartments of these regions represents scientific information for the assessment of the brain pathophysiology, including the neurovascular pathophysiology. This information, together with the qualitative information achieved by MRI has future possible clinical potential and may help Radiologists, Surgeons and Neurologists in the assessment of the neurovascular brain pathophysiology or therapies.

A MATHEMATICAL MODEL FOR THE THEORETICAL STUDY OF THE HAEMODYNAMICAL ASPECTS OF CHRONIC CEREBROSPINAL VENOUS INSUFFICIENCY

Lucas Mueller Omar, MS¹, Eleuterio Toro Francisco, PhD¹, David Utriainen, BS², Ewart Haacke Mark, PhD³ and Paolo Zamboni, MD⁴

¹University of Trento, Via Mesiano 77, Trento, TN, Trento, Italy

²Magnetic Resonance Innovations, Inc., 440 East Ferry Street, Detroit, MI 48202, USA

³Wayne State University, 3990 John R Road, Detroit, MI 48201, USA

⁴University of Ferrara, Ferrara, Italy

ABSTRACT:

Chronic Cerebrospinal Venous Insufficiency (CCSVI) is a recently described vascular condition¹ characterized by anomalous venous haemodynamics, which is caused by extracranial multiple venous strictures of various kinds and of unknown origin. The first step for a theoretical study on the haemodynamical aspects of CCSVI is the development of a mathematical model that correctly describes the physical problem. Here we present a mathematical model of the cardiovascular system constructed from first principles. Balance laws for mass and momentum lead to non-linear systems of differential equations, which are then solved with state-of-the-art numerical methods², resulting in an in-house simulation code. Given the interconnected nature of the venous system and thus the global character of CCSVI, we have constructed a closed-loop multi-scale model of the entire cardiovascular system. The heart, the pulmonary circulation and the peripheral circulation are modeled via lumped parameter models (0D). Major arteries and veins are modeled via one-dimensional (1D) formulations, including 240 major vessels. There are few examples in the literature of closed-loop multi-scale models of the cardiovascular system. To the best of our knowledge the one presented here is the first model that includes a 1D description of the venous system.

A distinct aspect of our model is the detailed description of the veins of head and neck. MRI data was used to segment major vessels of interest. The segmented vessels were then processed to extract centerline information and cross-sectional areas. For the smaller veins the geometric description was completed using information retrieved from the open literature. Flow data for major arteries and veins of the head and neck, as well as CSF flow between the intracranial subarachnoid space and the spine, were extracted from Phase Contrast MRI data for healthy controls³. The ability of the model to reproduce physiological flow patterns has been thoroughly validated using the gathered flow quantification data.

Figure 1 shows a comparison of PC-MRI flow quantification (symbols and dotted line) and numerical results (full line). While average flow rates agreement is satisfactory, waveforms present some differences. In the case of arteries, two factors should be considered to explain such differences: the time-resolution of flow data acquisition

and the fact that the mathematical model considers vessels as elastic, not taking into account part of wave damping due to the viscoelastic nature of vessels. Furthermore, we note that venous flow rate curves present two peaks, as expected. The first peak is caused by right-atrial pressure wave transmission and is in fact well reproduced by the model. The second peak is due to the transmission of arterial pressure to intracranial pressure and so to cerebrospinal fluid (CSF) and intracranial veins. Since the results shown do not include CSF and brain dynamics, the phase lag between modeled and measured waveforms is expected. We are working in the incorporation of a model that includes CSF and brain dynamics to our global model. This would allow full coupling of the interaction between the cerebral vasculature, ventricles and brain parenchyma.

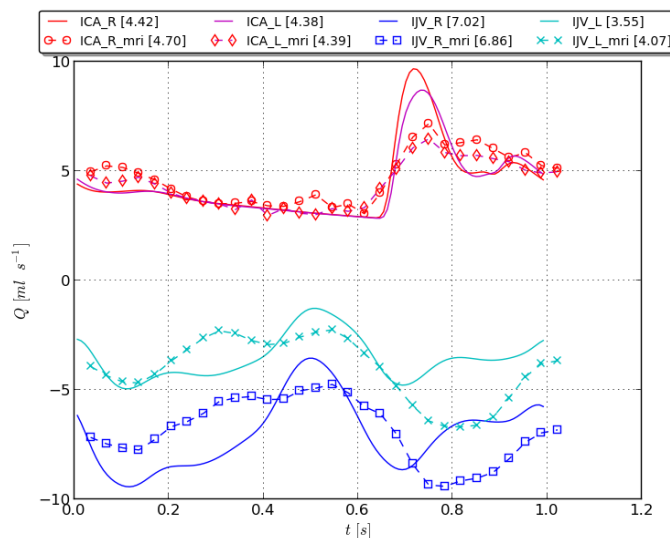


Fig. 1: Comparison between PC MRI data and numerical results for flow rates in internal carotid arteries (ICA) and internal jugular veins (IJV) at C2/C3 level for a healthy control. Numerical simulations are shown as continuous lines, whereas PC-MRI flow quantification data are shown as symbols linked by dotted lines. Average flow rates for each vessel shown in the legend between square brackets.

We are currently embarked on the theoretical study of haemodynamical aspects of CCSVI and results will be presented during the conference.

References

1. P Zamboni, R Galeotti, E Menegatti, AM Malagoni, G Tacconi, S Dall'Ara, I Bartolomei, F Salvi: *Chronic cerebrospinal venous insufficiency in patients with multiple sclerosis*, J Neurol Neurosurg Psychiatry 80:392-C399 (2009).
2. EF Toro: *Riemann solvers and numerical methods for fluid dynamics. A practical introduction*. Third edition. Springer-Verlag, Berlin Heidelberg, 2009. Book (724 pages). ISBN 978-3-540-25202-3, 2009.
3. W Feng, D Utriainen, G Trifan, S Elias, S Sethi, J Hewett, EM Haacke: *Characteristics of flow through the internal jugular veins at cervical C2/C3 and C5/C6 levels for multiple sclerosis patients using MR phase contrast imaging*. Neurological Research 34(8):802-9, 2012.

A COMPARATIVE STUDY OF MAGNETIC RESONANCE VENOGRAPHY TECHNIQUES FOR THE EVALUATION OF THE INTERNAL JUGULAR VEINS IN MULTIPLE SCLEROSIS PATIENTS

Md. Rahman Tamizur, MS¹, Sean Sethi Kumar, MS¹, David T. Utriainen, BS¹, J. Joseph Hewett, MD² and E. Mark Haacke, PhD³

¹Magnetic Resonance Innovations, Inc., 440 E Ferry Ave, Detroit, MI 48202, USA

²Synergy Health Concepts, 4501 Birch St, Newport Beach, CA 92660, USA

³Wayne State University, MR Research Facility, 3990 John R Road, Detroit, MI 48201, USA

ABSTRACT:

Background and Purpose

The use of magnetic resonance imaging (MRI) to assess the vascular nature of diseases such as multiple sclerosis (MS) is a growing field of research. This work reports on the application of MR angiographic (MRA) and venographic (MRV) techniques in assessing the extracranial vasculature in MS patients.

Materials and Methods

A standardized MRI protocol containing 2D TOF-MRV and dynamic 3D contrast-enhanced (CE) MRV was run for 170 MS and 40 healthy controls (HC). The cross-sectional area (CSA) of the internal jugular veins (IJVs) was measured at three neck levels in all subjects for both MRV techniques to determine the presence of venous stenoses.

Results

Of the 170 MS patients, 93 (55%) in CE-MRV and 103 (61%) in TOF-MRV showed stenosis in at least one IJV. The corresponding numbers for the 40 HC subjects were 2 (5%) and 4 (10%), respectively. Carotid ectasias with IJV stenosis were seen in 26 cases (15%) with 3D CE-MRV and were not observable with 2D TOF-MRV. Carotid ectasias were not seen in the HC group. In the 2D TOF-MRV data, banding of the IJVs related to slow flow was seen in 58 (34%) MS cases and in no HC cases. MS patients showed lower average CSAs than the HC subjects.

Conclusion

The 3D CE MRV depicted the vascular anatomy more completely than the 2D TOF-MRV. However, the 3D CE MRV does not provide any information about the flow characteristics which is indirectly available in the 2D TOF-MRV in those cases where there is slow flow.

Abbreviation key

cross-sectional area = CSA; healthy control = HC, internal jugular vein (IJV), CE = contrast-enhanced

ON MODELING TRANSPORT OF BOTH PLASMA AND SOLUTES ACROSS THE BLOOD-BRAIN BARRIER

Laura Facchini , MS, BS, Alberto Bellin, PhD, Eleuterio Toro Francisco, PhD

University of Trento, Via Sommarive, 14, Povo di Trento, Italy

ABSTRACT:

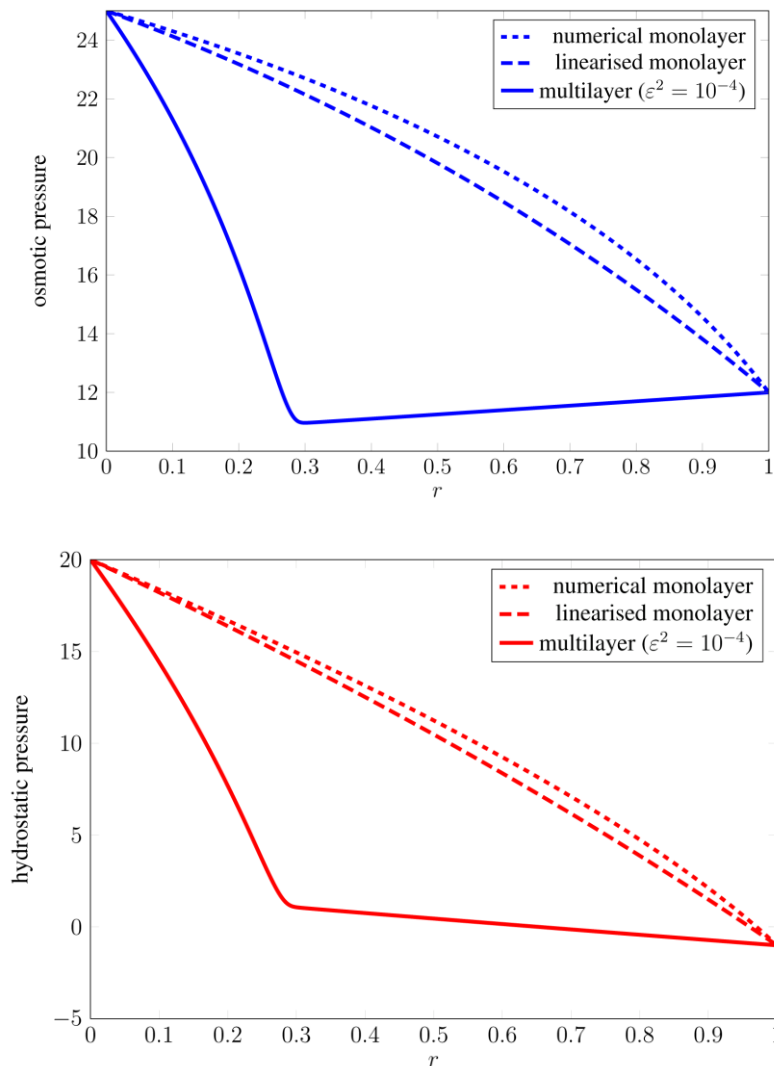
A completely healthy and integer vessel wall is able to transport gas and nutrients from the blood to the surrounding tissues, blocking harmful substances including bacteria. In the central nervous system (CNS) this is vitally important, so the cerebral vessel wall should be highly selective. The capillary wall of the CNS, called Blood-Brain Barrier (BBB), restricts bacteria and parasites, while allowing the passage of O_2 , CO_2 , water, hormones and metabolic products including glucose across it.

Since also antibodies, as well as drugs molecules, are too large to cross the BBB, the treatment of brain infections, including Lyme disease, syphilis, meningitis, brain abscess and epilepsy, are fraught of difficulties. For these reasons, the delivery of drugs across the BBB has been extensively studied.

Furthermore, the breakdown of the Blood-Brain Barrier with the associated increase of vessel permeability has been observed in many brain diseases, including stroke, traumatic head injury, Alzheimer's disease, AIDS, brain cancer, meningitis etc. (Li et al. 2010) and recently it has been associated with Multiple Sclerosis (Zamoni et al. 2009, Tucker 2011).

We present a one-dimensional mathematical model for filtration and transport of solute across a vessel wall thought as composed of two or more layers with different physical properties. We applied this model by using parameters and blood pressures data found in the literature. Our simulations showed that considering the BBB composed of layers with different functioning instead of a single homogeneous "equivalent" layer captures the reduction of the osmotic pressure at the contact of the glycocalyx with the endothelial cell described in the work of Adamson et al. (2004), thereby providing a realistic model of solute exchange across the vessel wall. The single layer model is not able to capture this behaviour.

We compare both volume and solute fluxes in a healthy vessel wall and in a damaged wall, where the glycocalyx shows some leakage due to the damage. In the damaged vessel we observe an increase of liquid and macromolecules leaked from the damaged vessel wall, compared to the integer wall. However, in undamaged wall the increase of the blood pressure can also increase water and mass flow through the vessel wall.



Variation of hydrostatic (red curves) and osmotic pressures (blue curves) across the vessel wall, computed both in the mono-layer case with parameters chosen such that flux of both plasma and solute remain the same (dashed curves) and in the two-layer case (solid curves).

REFERENCES

- Li G., Yuan W., Fu B. M., 2010, A model for the blood–brain barrier permeability to water and small solutes, *Journal of Biomechanics* 43(11):2133–2140.
- Zamoni P., Galeotti R., Menegatti E., Malagoli A. M., Ganesini S., Bartolomei I., et al., 2009, Prospective open-label study of endovascular treatment of chronic cerebrospinal venous insufficiency, *J. Vas. Med.* 50(5): 1348–1358.
- Tucker T. W., 2011. A physics link between venous stenosis and multiple sclerosis, *Medical hypotheses* 77(6):1074–8. doi: 10.1016/j.mehy.2011.09.006.
- Adamson R. H., Lenz J. F., Zhang X., Adamson G. N., Weinbaum S., Curry F. E., 2004. Oncotic pressures opposing filtration across non-fenestrated rat microvessels, *J Physiol* 557(3): 889–907.

A THREE MONTH AND ONE YEAR EVALUATION WITH COLOR DOPPLER ULTRASOUND OF THE ENDOVASCULAR TREATMENT IN PATIENTS WITH CEREbro-SPINAL VENOUS INSUFFICIENCY

Elena Righi, MD, Giovanni Bellagamba, MD, Isac Flaishman, MD, Vincenzo Di Donna, MD, Paolo Onorati, MD, Tommaso Lupattelli, MD
ICC-GVM Sanita, Alessandro Magno 386, Rome, Italy

ABSTRACT:

Purpose

To assess the result of PTA with color Doppler ultrasound at three months and one year in a cohort of patients with cerebro-spinal venous insufficiency (CCSVI).

Materials and Methods

Between December 2010 and September 2011, 577 patients with CCSVI and multiple sclerosis (252 RR, 246 SP, 54 PP and 25 not well defined form) and 17 patients with CCSVI and other neurological disorders underwent transluminal percutaneous angioplasty of one or both jugular veins +/- azygous vein. In a few cases the left anonymous vein and/or left iliac vein were also treated. No stents were ever implanted in the jugular, anonymous or iliac veins, being only deployed in the azygous vein in very selected cases. All patients had been previously studied with color Doppler ultrasound and found positive to CCSVI for the presence of at least 2 criteria of Zamboni. All 592 patients were operated by the same interventionist (T.L.) at a single center (Villa Salus, RE). Technical success of PTA was regarded as evidence of less than 2 Zamboni criteria at color Doppler ultrasound performed within 24 hours from the procedure. During the follow up, color-Doppler ultrasound examination was carried out at three months and one year. Recurrence of the disease was regarded as evidence of 2 or more criteria of Zamboni.

Results

Successful angioplasty accounted for 561 patients (94,7%). Of all patients, 536 (90,5%) completed the color Doppler ultrasound follow-up at three months and 403 (68,7%) at one year. Among patients with successful PTA, color Doppler ultrasound was completed from 511 patients (91,1%) at three months and from 385 patients (68,6%) at one year. The overall success of the procedure at three months and one year was 86,8% (465 out of 536 patients) and 76,4% (308 out of 403 patients), respectively. Among patients with successful endovascular treatment the absence of CCSVI recurrence was as high as 91% (465 out of 511 patients) at three months and 80% (308 out of 385) at one year. Prior to PTA, the mean number of Zamboni criteria in the whole group of patients treated was 3,63 whereas at 3 months and one year it decreased to 1,19 and 1,32 respectively.

Conclusion

Endovascular treatment of CCSVI shows a high rate of success. At one year, the rate of disease recurrence is relatively low, accounting for about 20% of patients. Further studies on larger number of patients may be necessary in order to confirm these data.

CHRONIC CEREBRO-SPINAL VENOUS INSUFFICIENCY: DUPLEX ULTRASOUND FINDINGS IN MULTIPLE SCLEROSIS PATIENTS AND HEALTHY CONTROLS

Isac Flaishman, MD, Giovanni Bellagamba, MD, Elena Righi, MD, Paolo Onorati, MD and Tommaso Lupattelli, MD

ICC-GVM Sanita, Alessandro Magno 386, Rome, Italy

ABSTRACT:

Abstract

Multiple Sclerosis (MS) represents the major not traumatic cause for neurologic disability in young adults. During the last years chronic cerebro-spinal venous insufficiency (CCSVI) was described by Zamboni et al as a clinical condition that may have a role in the pathogenesis of MS symptoms. Although different reports tried to establish the incidence of CCSVI in SM patients controversies are still open regarding the diagnosis and the existence of CCSVI in these patients. We report our experience of CCSVI incidence in MS and healthy population that were studied by means of duplex scan exam according to Zamboni method and criteria.

Patients and Methods

Between December 2011 and May 2012 fifty patients affected by MS (group A) and 50 patients not affected by MS (group B) underwent duplex scan examination of the extra and intra-cranial venous system in order to evaluate the presence of CCSVI. All patients were examined by the same operator, with large experience in duplex ultrasound exams, with Esaote Mylab Vinco machine in supine and sitting position. Examination was carried out according to Zamboni method looking for his criteria of CCSVI.

Results

The two groups were homogeneous regarding age (mean age in group A 34 years, group B 41 years) and gender. Among group A there were 37 patients (74%) with RR-MS, 7 patients with SP-MS (14%) and 6 patients with PP-MS (12%). All the patients in group B were healthy patients who were studied during a carotid artery duplex-scan exam performed for other reasons. Duplex-scan findings in group A showed the presence of CCSVI in 45 patients (90%). Only 5 patients in group A did not show to have 2 or more Zamboni criteria for CCSVI. All the 5 patients were patients with RR-MS. Among the patients with CCSVI all had deep cerebral veins reflux, internal jugular veins (IJV) reflux both in supine and sitting position and high resolution B-Mode evidence of stenosis. Lack of doppler-detectable flow in the IJV was found mainly in PP-MS and SP-MS. Patients. The incidence of CCSVI among patients of group A did not showed any statistical difference regarding the clinical type of MS. In group B there were no patients with Zamboni criteria for CCSVI ($p < 0,01$). The most frequent findings in group B were IJV reflux and high resolution B-mode stenosis. The mean number of Zamboni criteria in group A was 3,75 and in group B 0,65 ($p < 0,01$).

Conclusion

Our data showed a significantly higher incidence of CCSVI in MS patients group as compared to healthy patients. Further studies on larger number of patients may be necessary in order to confirm these data. The experience of the duplex-scan operator is of primary importance in order to detect correctly CCSVI in MS patients.

COMPUTATIONAL HAEMODYNAMICS IN STENOTIC INTERNAL JUGULAR VEINS

Alfonso Caiazzo, PhD¹, Gino Montecinos, MS¹, Lucas Mueller Omar, MS¹, Eleuterio Toro Francisco, PhD¹, Ewart Haacke Mark, PhD²

¹Università di Trento, via Mesiano 77, Trento, TN, Trento, Italy

²Wayne State University, 3990 John R Road, Detroit, MI 48201, USA

ABSTRACT:

Extracranial venous stenoses are associated to CCSVI [1], as one of the causes of anomalous cerebral venous outflow and cerebral pressure increase [2]. Stenoses are normally defined according to generic anatomic criteria, such as the reduction of jugular veins cross-sectional area (CSA). However, CSA reduction might have different impact, according to individual anatomical features.

The aim of this work is to achieve a quantitative assessment of the influence of IJV stenoses on cerebral haemodynamics in patient specific contexts. We introduce a framework based on computational fluid dynamics (CFD), combining a mathematical model for the blood flow in the jugular veins with Magnetic Resonance Imaging (MRI) and anatomical data [3]. Patient-specific 3D geometries of IJVs, brachiocephalic veins and Superior Vena Cava (SVC) have been extracted from Time-Of-Flight (TOF) images and segmented using a level-set based segmentation. In order to study the relevance of different stenotic configurations, we developed a computational procedure to *locally* reduce the CSA of the original geometries. The incompressible Navier-Stokes equations have been solved using up-to-date finite element methods, both on the original and on the deformed geometries [4]. Flow data acquired with phase-contrast MRI were set as boundary conditions at the IJVs inlets. Physiologic flow rates and pressure were assigned at subclavian veins inlet and SVC outlet, respectively.

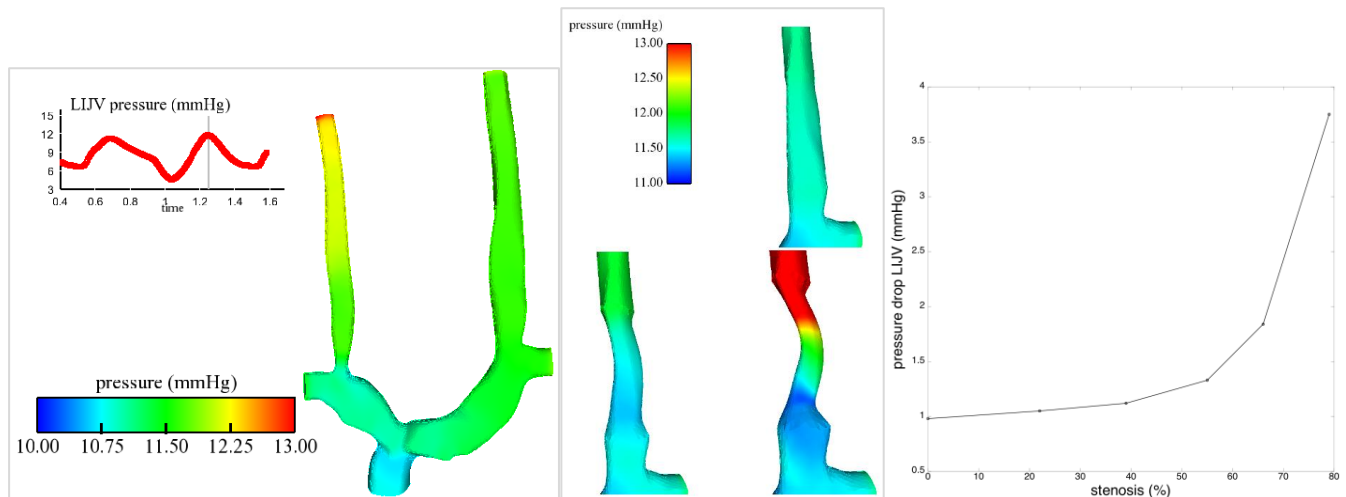


Figure 1 **Left.** Snapshot of a CFD simulation on the original geometry. The top-left curve depicts the inlet IJIV pressure over time. **Center.** Detailed simulation results for pressure near the stenosis for the modified geometries, with increasing degrees of obstruction (respectively 20%, 40% and 80%). **Right.** Maximum pressure drop (in mmHg) across the stenotic IJIV (over a cycle), as a function of the reduction of CSA (in %).

Figure 1 shows a set of preliminary results for a stenotic IJIV. In particular, in the original configuration (Fig.1, left) the pressure difference between IJIVs inlet and outlet is around 1 mmHg, while, in the case of a stenosis, we observe that a significant increase in IJIV pressure drop (above 1.5 mmHg) is achieved with a reduction of the CSA of more than 50% (Fig. 1, center and right). Further results will be presented during the conference.

This work represents a first step towards a computer-aided understanding of CCSVI haemodynamics in a patient-specific context. Future developments will focus on the implementation of Fluid-Structure Interaction models to account for veins compliance, and on the incorporation of this framework into a multi-scale global model of the cardiovascular system.

Acknowledgement

Part of this work has been sponsored by "Fondazione Cassa Di Risparmio di Trento e Rovereto".

References

- [1] P. Zamboni, R. Galeotti, E. Menegatti, A. M. Malagoni, G. Tacconi, S. Dall'Ara, I. Bartolomei and F. Salvi, *Chronic cerebrospinal venous insufficiency in patients with multiple sclerosis*, J. Neurology, Neurosurgery and Psychiatry **80**:392-399 (2009)
- [2] T.W. Tucker, *A physics link between venous stenosis and multiple sclerosis*, Med. Hypoth. **77**:1074-1078 (2011)
- [3] W. Feng, D. Utriainen, G. Trifan, S. Elias, S. Sethi, J. Hewett and E.M. Haacke, *Characteristic of flow through the internal jugular veins at cervical C2/C3 and C5/C6 levels for multiple sclerosis patients using MR phase contrast imaging*, Neur. Research **34**(8):802-809 (2012)
- [4] K. McLeod, A. Caiazzo, M.A. Fernandez, T. Mansi, I.E. Vignon-Clementel, M. Sermesant, X. Pennec, Y. Boudjemline and J.F. Gerbeau, *Atlas-Based Reduced Models of Blood Flows for Fast Patient-Specific Simulations*. Proc. of MICCAI 2010, Springer LNCS **6364**:95-104 (2010)

FEASIBILITY AND SAFETY OF ENDOVASCULAR TREATMENT FOR CHRONIC CEREBROSPINAL VENOUS INSUFFICIENCY IN A COHORT OF 1202 PATIENTS WITH MULTIPLE SCLEROSIS

Tommaso Lupattelli, MD, Giovanni Bellagamba, MD, Elena Righi, MD, Isac Flaishman, MD, Vincenzo Di Donna, MD, Eleonora Farina, MD and Paolo Onorati, MD
ICC-GVM Sanita, Alessandro Magno, Rome, Italy

ABSTRACT:

Introduction

Chronic cerebrospinal venous insufficiency (CCSVI) is a recently discovered syndrome mainly due to stenoses of internal jugular (IJV) and/or azygos (AZ) veins. The aim of the present study is to retrospectively evaluate the feasibility and safety of endovascular treatment for CCSVI in a cohort of patients with multiple sclerosis (MS).

Materials & Methods

From September 2010 to October 2012, 1202 patients underwent selective Phlebography \pm endovascular recanalization at two different Italian centers. All the patients had previously been found positive at color Doppler ultrasound for at least two Zamboni criteria for CCSVI and had a neurologist confirmed diagnosis of MS. Only symptomatic MS were considered for treatment. Left common iliac, ascending lumbar, vertebral and internal, jugular veins as well as azygos territory were selectively studied in all cases. The interventional treatment, was carried out as an outpatient procedure in all patients. All the procedures were performed by an experienced interventional radiologist (T.L) with a good knowledge of venous endovascular interventions. Technical success was regarded as the capability to selectively catheterize both IJVs and AZ as well as to perform PTA, when needed. Technical success and complications occurred at 30 days were recorded. Transient chest, neck pain or headache were regarded as typical symptoms after the procedure and were not registered as adverse events.

Results

Phlebography followed by endovascular recanalization was carried out in 1994 patients for a total of 1214 procedures. In 5 additional patients (5 cases) the decision to carry out the interventional procedure was solely taken after phlebography because of uncertain diagnosis of CCSVI at color Doppler ultrasound. Three patients (three cases) with diagnosis of CCSVI at Color Doppler ultrasound were not treated endovascularly because no significant disease in at least one IJV was seen at phlebography.

Procedural success for obtaining selective catheterization +/- angioplasty of all three target vessels was achieved in 1192 patients (99,2%) and 1212 procedures (99,2%). In fact, in three patients selective study of one target vessel was not possible due to a vein agenesis (one left IJV and two azygos vein), whereas in 7 patients complete occlusion/thrombosis of one IJV (two on the right and five on the left side) due to a previous endovascular treatment was seen. Balloon angioplasty alone was performed in 1185 out of 1199 patients (98,8%) and in 1205 out of 1219 procedures (98,9%) whereas additional stent placement was required in the remaining 14 patients (1,2%) and 14 procedures (1,1%) following unsuccessful attempts at azygos dilatation. No stents were ever implanted in the IJV.

Complications were calculated on the whole number of patients treated with angioplasty +/- stenting (1199 patients). Major complications included one (0,1%) azygous vein rupture occurred during balloon dilatation and requiring blood transfusion, one (0,1%) severe bleeding in the groin requiring open surgery, two (0,2%) surgical openings of the common femoral vein to remove balloon fragments and three (0,25%) left IJV thromboses. The overall rate of major and minor complications in the study population was 06% and 2,5%, respectively.

Conclusion

Endovascular treatment for CCSVI appear feasible and safe. However, a proper learning curve can dramatically lower the rate of complications. In our experience, the vast majority of complications occurred in the first 400 cases performed.

EXTERNAL COMPRESSION OF LEFT INTERNAL JUGULAR VEIN OR BRACHIOCEFALIC VEIN IN PATIENTS WITH CHRONIC CEREBROSPINAL VEIN INSUFFICIENCY AND MULTIPLE SCLEROSIS

Tommaso Lupattelli, MD and Giovanni Bellagamba, MD
ICC-GVM Sanita, Alessandro Magno, Rome, Italy

ABSTRACT:

Background

Multiple sclerosis (MS) is a chronic and debilitating disease of the central nervous system that has been found to be associated with chronic cerebrospinal venous insufficiency (CCSVI), a unique venous pathology that is comprised of stenoses and occlusions mainly in the extracranial (azygous and internal jugular) veins draining the central nervous system. Zamboni et al have proposed 5 criteria to assess venous abnormalities such as reflux/bidirectional flow, absence of flow and others in both sitting and supine positions. Moreover, he postulated that venous pathology in CCSVI patients is often related to presence of a valve abnormality at the vein outlet, particularly in the IJVs. According to Zamboni, the major anomalies which can be found at the level of the IJV valve are: flap, septum, annulus, immobile leaflets, immobility limited to one of the two leaflets, double channels, anomalous orientation of the valve leaflets ecc. However, in some patients, an anomalous compression of the IJVs as well as the (right) anonymous or (left) brachiocephalic vein due to presence of (anomalous) surrounding structures such as bones, arteries or muscles can be seen. The aim of our study is to retrospectively evaluate at phlebography the prevalence of an outer compression of the IJVs as well as the anonymous and brachiocephalic veins in patients with CCSVI and MS. Also, the role of balloon dilatation for the treatment of this new evidence is investigated.

Materials and Methods

Between September 2010 and September 2012 a total of 1202 patients with CCSVI and MS underwent phlebography +/- PTA at our institute. Super-selective phlebography with a dedicate 6 F catheter was performed in both internal jugular, anonymous, brachiocephalic and azygous veins. Left common iliac, ascending lumbar and vertebral veins were also investigated. All the procedures were carried out by an experienced interventional radiologist (T.L) with a good knowledge of venous endovascular interventions. With regard to phlebography of the IJV, an anterior-posterior view was first obtained, with the head of the patient kept in the ordinary position. Afterwards, an anterior-posterior view was obtained with the head turned to the other side of the IJV that was being investigated. All other vessels were studied with an antero-posterior view and additional lateral and oblique views in case of an uncertain diagnosis.

Results

Diagnostic phlebography of both IJVs as well as azygous vein was carried out in all but eight patients. In these eight patients super-selective study of one IJV vein was not obtained due to vessel agenesis (1 case) or vessel thrombosis (7 cases) due to a previous endovascular intervention. Therefore these 8 patients were excluded from the present study. 76 (6,4%) out of the remaining 1194 patients showed an outer compression of the IJV (71 on the left and 5 on the right side) leading to significant delay in the contrast medium drainage towards the vena cava. Compressions were localized either at the mid portion of the IJV (93,4%) or at the level of the vein outlet (6,6%) and showed to be unresponsive to balloon dilatations in all cases. However, in greater than 90% of patients significant improvements of blood flow discharge was noted with the head of the patients turned to the opposite site of the affected IJV. 6 (0,5%) patients presented with brachiocephalic vein narrowing which proved to be irresponsive to either angioplasty and change in the head position. Finally, no blood flow improvement was seen despite several attempts at balloon dilatation of the vein were made. Contrast-enhanced CT scan performed within 24 hours showed evidence of external vein compression/entrapment in all of these 6 patients. No outer compressions of the anonymous vein were registered in the present series. The overall rate of external compression in the whole group of patients in whom phlebography was obtained in both IJV was as high as 6,9%.

Conclusion

Outer compression due to presence of anomalous structures surrounding the IJVs and/or anonymous and brachiocephalic vein is a new evidence of possible delay in the blood flow drainage from the brain to the heart. Balloon dilatation proved to be ineffective in all cases. Further studies on larger number of patients are required to better evaluate this problem.

EFFECT OF OREXIN-A AND SB-334867 INJECTION ON INFARCTION SIZE AND RECOVERY OF FUNCTION ON A FOCAL TRANSIENT STROKE MODEL; ROLE OF NITRIC OXIDE

Arash Esmaeili, MD and Pegah Bikdeli, MD

Tehran University of Medical Sciences, No.7, West Madani Alley, Dastgheib St.,
Nastaran St., Ashrafi Esfahani Blvd., Tehran, Iran

ABSTRACT:

Orexins (orexin-A and orexin-B) were discovered in 1998 in hypothalamus and initially characterized as potent appetite stimulating neuropeptides, but the widespread and distinct distribution of the orexin receptor suggests a various roles of orexins in addition to control of feeding.

Recent studies suggest that the novel neuropeptide orexin-A may play a neuroprotective role during neuronal damage by increasing cerebral blood flow. Therefore, in the current study, we have examined expression of endothelium derived-NO (eNOS) as a vasodilator and neurodegenerative mediator like inducible NO (iNOS) and neuronal NO (nNOS) via quantitative reverse transcription polymerase chain reaction (RT-PCR), to investigate the mechanisms of neuroprotective activity of orexin-A and augmentation of cerebral blood flow following transient occlusion of the middle cerebral artery in the rat.

Thirty-two adult male Wistar rats (200–250 g) were randomly alienated into four groups: sham-operated, control, orexin-A, and orexin-A plus orexin-A antagonist (SB334867).

The induction of transient focal ischemia model was generated by performing middle cerebral artery occlusion (MCAO) for 120 minutes followed by reperfusion.

At 48 hours after MCAO, brains were removed and sectioned into 2-mm-thick coronal slices. These slices were stained in saline containing 2% 2,3,5-triphenyltetrazolium chloride (TTC) for 15 min at 37°C for measuring extent of infarction volume. In addition, quantitative RT-PCR was performed for iNOS, nNOS and eNOS. Neurologic scores evaluated at 2 and 48 hours after reperfusion in all groups.

Mean percentage of infarction volume in the control group was 55.4%, whereas Orexin-A (0.3nmol/kg) administration markedly attenuated total infarct volume. In contrast, administration of SB334867 significantly covers up neuroprotective effect of orexin-A 48 hours after reperfusion.

Administration of orexin-A significantly decreased expression of iNOS and nNOS. However expression of eNOS showed significant increase in orexin-A treated animals. These results suggest that Orexin-A has a neuroprotective effect against cerebral ischemia-reperfusion injury. These effects may be mediated through the vasodilatory effect of eNOS and reduction of iNOS and nNOS expression.

CHANGES OF CINE CEREBROSPINAL FLUID DYNAMICS IN MULTIPLE SCLEROSIS PATIENTS TREATED WITH VENOUS ANGIOPLASTY

Robert Zivadinov^{1,2}, Christopher Magnano¹, Roberto Galeotti³, Erica Menegatti³, Bianca Weinstock-Guttman², Ilaria Bartolomei⁴, Anna Maria Malagoni³, Clive Beggs⁵, Fabrizio Salvi⁴, Paolo Zamboni³

¹ Buffalo Neuroimaging Analysis Center, University at Buffalo, NY, USA

² The Jacobs Neurological Institute, University at Buffalo, Buffalo, NY, USA

³ Vascular Disease Centre, University of Ferrara, Ferrara, Italy

⁴ Bellaria Neurosciences, Bologna, Italy

⁵ Centre for Infection Control and Biophysics, University of Bradford, Bradford, UK

ABSTRACT:

Background

To investigate characteristics of cine phase contrast-calculated cerebrospinal fluid (CSF) flow and velocity measures in patients with relapsing-remitting (RR) MS on standard medical treatment, who were diagnosed with chronic cerebrospinal venous insufficiency (CCSVI), and underwent venous angioplasty.

Materials and Methods

This was a case-control MR blinded 12 months study that included 15 patients with RRMS who presented with CCSVI-Doppler detected venous abnormalities. Eight patients underwent venoplasty in addition to medical therapy immediately following baseline assessments, while 7 had delayed treatment with venoplasty after 6 months of medical therapy alone. CSF flow and velocity measures were quantified over 32 phases of the cardiac cycle using a semi-automated method. Outcomes were compared between immediate and delayed treatment groups at baseline, 6 and 12 months of the study.

Results

At baseline, no significant differences in CSF flow or velocity measures were detected between the 2 treatment arms. At month 6, significant change in both flow ($p < 0.001$) and velocity ($p = 0.013$) were detected in the immediate compared to delayed treatment groups, persisting to month 12 ($p = 0.001$ and $p = 0.021$, respectively). Within-group flow comparisons from baseline to follow-up showed significant increase in the immediate treatment group ($p = 0.033$), but decrease in the delayed treatment group ($p = 0.024$). Altered CSF flow and velocity measures were associated with worsening of clinical and MRI outcomes in delayed treatment arm.

Conclusion

Venoplasty treatment of MS patients with CCSVI had a beneficial effect on CSF flow and velocity measures, which could be related to better venous drainage.

INTERPRETATION OF CERVICAL PLETHYSMOGRAPHY DATA WITH RESPECT TO THE DIAGNOSIS OF CHRONIC CEREBROSPINAL VENOUS INSUFFICIENCY

Clive Beggs, PhD¹, Simon Shepherd, PhD¹, Erica Menegatti, PhD², Paolo Conforti, MD², Mirko Tessari, RVT² and Paolo Zamboni, MD²

¹Medical Biophysics Laboratory, University of Bradford, Richmond Road, West Yorkshire, Bradford, UK

²Vascular Diseases Centre, University of Ferrara, Ferrara, Italy

ABSTRACT:

Introduction

There is considerable debate regarding the applicability of magnetic resonance imaging and echo color Doppler (ECD) scan techniques for assessing cerebral venous return [1]. This has generated much scientific controversy regarding the diagnosis of chronic cerebrospinal venous insufficiency (CCSVI) [2, 3], which is characterized by restricted venous outflow from the brain. It is however possible to assess cerebral venous return in relation to the change in a subject's position by means of a novel cervical plethysmography method, which utilizes a passive strain-gauge collar [4]. While the new cervical plethysmography technique has great potential as a low cost diagnostic tool for CCSVI, much remains unknown about the haemodynamics associated with this procedure. The aim of this study was therefore to gain a deeper understanding of the observed haemodynamics associated with this new diagnostic tool.

Materials & Methods

In a single-center, cross-sectional, blinded case-control study, 40 healthy controls and 44 CCSVI patients underwent cervical plethysmography. All participants were previously scanned using ECD sonography and separated into two subsets, a control group and a CCSVI group. The plethysmography procedure involved placing a strain-gauge collar around the subjects' necks and tipping them from the upright (90°) to supine position (0°) in a chair. Once stabilized, they were returned to the upright position, allowing blood to drain from the neck. Measured outcomes included venous volume (VV), filling time (FT), filling gradient (FG) required to achieve 90% of VV, residual volume (RV), emptying time (ET), and emptying gradient (EG) required to achieve 90% of emptying volume (EV), where $EV = VV - RV$. A novel mathematical model was developed to calculate the hydraulic resistance of the extracranial venous system for each subject in the study [5].

Results

The rate at which venous blood discharged in the vertical position (EG) was significantly faster in the controls ($2.73 \text{ mL/second} \pm 1.63$) compared with the patients with CCSVI ($1.73 \text{ mL/second} \pm 0.94$; $P = 0.001$). In addition, respectively, in controls and in patients with CCSVI, the following parameters were highly significantly different: FT 5.81 ± 1.99 seconds vs 4.45 ± 2.16 seconds ($P = 0.003$); FG $0.92 \pm 0.45 \text{ mL/second}$ vs $1.50 \pm 0.85 \text{ mL/second}$ ($P < 0.001$); RV $0.54 \pm 1.31 \text{ mL}$ vs $1.37 \pm 1.34 \text{ mL}$ ($P = 0.005$); ET 1.84 ± 0.54 seconds vs 2.66 ± 0.95 seconds ($P < 0.001$). The mean hydraulic resistance of the extracranial venous system was 10.28 (SD 5.14) mmHg.s/mL in the healthy controls and 16.81 (SD 9.22) in the CCSVI patients ($p < 0.001$).

Conclusion

Cerebral venous return haemodynamics of the patients with CCSVI were markedly different from those of the controls, with the hydraulic resistance of the CCSVI patients being on average 63.5% greater in the CCSVI patients. As such, this appears to corroborate Monti *et al* [6], who found reduced cerebral venous outflow in the upright position to be strongly associated ($p < 0.0001$) with MS. Given that CCSVI has been shown by many researchers to be associated with MS [7-9], this suggests the presence of abnormal cerebral venous drainage hydrodynamics in many patients with MS [6]. Furthermore, the results suggest that cervical plethysmography has great potential as an inexpensive screening device and as a postoperative monitoring tool.

References

- (1) Dolic K, *et al.* *AJNR Am J Neuroradiol* 2012; 33: 16–23;
- (2) Doepp F, *et al.* *Ann Neurol* 2010; 68: 173–183;
- (3) Beggs C. *Ann Neurol* 2010; 68: 560–561;
- (4) Zamboni P, *et al.* *J Vasc Surg* 2012; 56: 677–685;
- (5) Beggs C, *et al.* *Phlebology*. 2012; (Epub ahead of print);
- (6) Monti L, *et al.* *PLoS One* 2011; 6: e25012;
- (7) Zamboni P, *et al.* *J Neurol Neurosurg Psychiatry* 2009; 80: 392–399;
- (8) Zivadinov R, *et al.* *BMC Neurology* 2011; 11: 128;
- (9) Zamboni P, *et al.* *Funct Neurol* 2009; 24: 133–138.

THE IMPACT OF CHRONIC CEREBROSPINAL VENOUS INSUFFICIENCY ON INTRACRANIAL PHYSIOLOGY IN HEALTHY INDIVIDUALS

Clive B. Beggs, PhD¹, Christopher Magnano, MS², Simon J. Shepherd, PhD¹, Karen Marr, RVT², Vesela Valnarov, MD², David Hojnacki, MD³, Niels Bergsland, BS², Pavel Belov², Steven Grisafi², Michael G. Dwyer, MS¹, Ellen Carl¹, Bianca Weinstock-Guttman, MD³, Robert Zivadinov, MD, PhD^{2,3}

¹Centre for Infection Control and Biophysics, University of Bradford, Bradford, West Yorkshire, Bradford, UK

²Buffalo Neuroimaging Analysis Center, University at Buffalo, Buffalo, NY, USA

³Jacobs MS Comprehensive and Research Center, University at Buffalo, Buffalo, NY, USA

ABSTRACT:

Introduction

In recent years it has been observed that many patients with multiple sclerosis (MS) exhibit stenosis of the extra-cranial venous pathways from the brain [1], resulting in extensive collateral rerouting of the blood back to the heart [2]. Given that this condition, known as chronic cerebrospinal venous insufficiency (CCSVI), is associated with alterations in the cerebral vascular bed [3] and CSF dynamics [4], there is reason to believe that occlusion of the extra-cranial venous pathways might cause subtle changes of the cerebral hydrodynamic system. If this were the case, then one would expect these changes to be evident in healthy individuals, with no neurological disorder, who are diagnosed with CCSVI. Therefore, in this study we investigated this possibility and present the results of a preliminary study designed to establish whether or not CCSVI is associated with hemodynamic and structural brain parenchyma changes in healthy individuals.

Materials & Methods

25 CCSVI negative and 15 CCSVI positive age- and sex-matched healthy individuals with no known neurological disease underwent Doppler sonography (DS) and MRI scan with cine phase contrast imaging for cerebrospinal fluid (CSF) flow estimation. CSF net negative flow (NNF), net positive flow (NPF), peak positive velocity (PPV) and peak negative velocity (PNV), T2 lesion number (T2-LN) and volume (T2-LV) and normalized gray matter volume (GMV), white matter volume (WMV), lateral ventricle volume (LVV) and cortical volume (CV) were collected. Univariate and multivariate (MANOVA) statistical analysis of the data was undertaken, together with principal component analysis (PCA), logistic regression analysis (LRA) and singular value decomposition (SVD) cluster analysis to identify differences between the two study groups.

Results

LRA revealed a combination of NPF ($p = 0.009$), T2-LN ($p = 0.009$) and T2-LV ($p = 0.007$) to be the best discriminator between the CCSVI positive and negative cohorts, achieving sensitivity and specificity scores of 73.3% and 80.0%, respectively. SVD analysis confirmed this result (sensitivity = 80.0%; specificity = 88.0%). PCA revealed marked differences in the system dynamics between the CCSVI positive and negative groups; a finding confirmed by the results of the MANOVA ($p = 0.033$). CCSVI was associated with increased NPF ($p = 0.037$; Mann-Whitney U-test) and NNF ($p = 0.086$; Mann-Whitney U-test). In the CCSVI negative group the correlation between normalized LVV and T2-LN was very weak ($r = 0.152$, $p = 0.469$), whereas in the CCSVI positive group this relationship was much stronger ($r = 0.662$, $p = 0.007$).

Conclusion

CCSVI appears to be associated with systemic changes in the intracranial physiology of healthy individuals, which alters the relationship between the CSF flow, enlargement of LVV and T2 lesion formation. CCSVI negative individuals exhibit a complex intracranial dynamic, which appears to simplify in CCSVI positive individuals. Correlations between key MRI variables are much stronger in the CCSVI positive group compared with the negative group, suggesting that some intracranial variables have become more dominant. In particular, relationships involving LVV and other MRI variables significantly altered in the CCSVI positive group. The results of the study mirror those of other researchers who observed increased CSF pulsatility in MS patients [4, 5] – something that appears to be associated with CCSVI [4]. Although not statistically significant, CSF net flow (sum of NNF and NPF) was 27.1% lower in the CCSVI positive group compared with the CCSVI negative group. As such, this finding is consistent with the model that CCSVI induces hypertension in the dural sinuses, something that is known to inhibit CSF absorption from the sub-arachnoid space [6].

References

- (1) Zamboni P, et al. *J Neurol Neurosurg Psychiatry* 2009; 80: 392-399; (2) Zamboni P, et al. *Current Neurovascular Research* 2009; 6: 204-212; (3) Zivadinov R, et al. *BMC Neurology* 2011; 11: 128; (4) Zamboni P, et al. *Funct Neurol* 2009; 24: 133-138; (5) Magnano C, et al. *J Magn Reson Imaging* 2012; 36: 825-834. (6) Cutler RW, et al. *Brain* 1968; 91: 707-720

INFLUENCE OF BODY POSITION CHANGE ON CROSS SECTIONAL AREA (CSA) OF INTERNAL JUGULAR VEINS (IJVs) AND VERTEBRAL VEINS (VVs) IN HEALTHY SUBJECTS

Sandra Morovic, MD, PhD and Vida Demarin, MD, PhD, FAAN, FAHA, FESO

Medical Centre Nemetova, Nemetova 2, Zagreb, Croatia

ABSTRACT:

Introduction

The value of venous outflow has been greatly underestimated in clinical practice and research. Evidence exists that venous anomalies play an important role in manifestation of neurological disorders, especially in neurodegenerative disorders. Neurological disorders associated with venous malfunction are multiple sclerosis, optic neuritis, transverse myelitis, vascular damage to nerves, transient global amnesia, transient blindness, cerebral hypoperfusion, cough headache, primary exertional headache, idiopathic intracranial hypertension, hydrocephalus, leukoariosis.

It has already been proven that the main outflow route changes as we change position from supine to sitting. In supine position the main outflow route are the IJVs, while in sitting position the main outflow route are VVs. The diameter change of IJVs at J2 point following body position change has already been proven, but there is not much data showing vertebral vein diameter changes when changing position from supine to sitting.

Aim

The aim of this study is to compare diameter changes in internal jugular veins and vertebral veins following body position change, knowing that the outflow route changes in healthy subjects when they change position from supine to sitting.

Methods

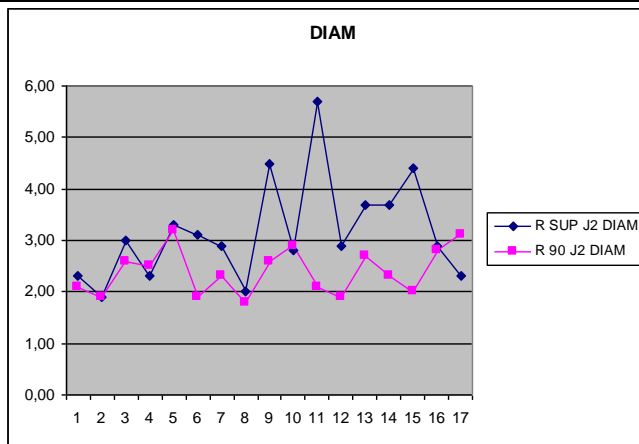
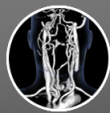
17 healthy volunteers were examined. Color Doppler of the venous system of the head and neck was performed. Diameter measurements were taken at 8 points in each subject: J1, J2, and J3 points of both IJVs, and V2 points of both VVs.

Results

(please see table below)

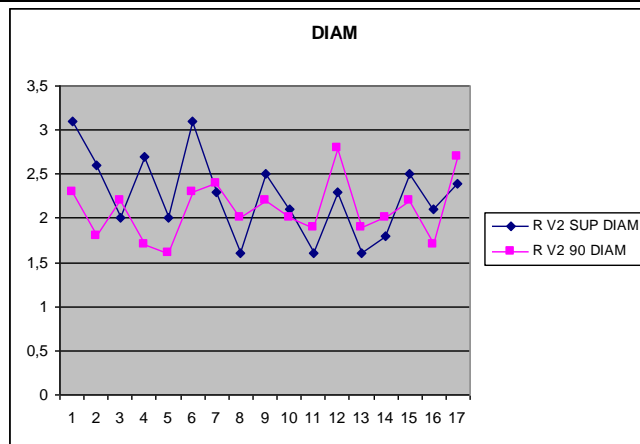
Discussion

Our data generally showed diameter changes at J2 point of both left and right IJVs resulting from position change from supine to sitting. In some subjects, these changes are small or absent at J2 point of right IJV (IJV R), but there may be an indication that this difference is compensated by diameter changes of V2 point of the right VV (V2 R). This may show a blood flow consistency.



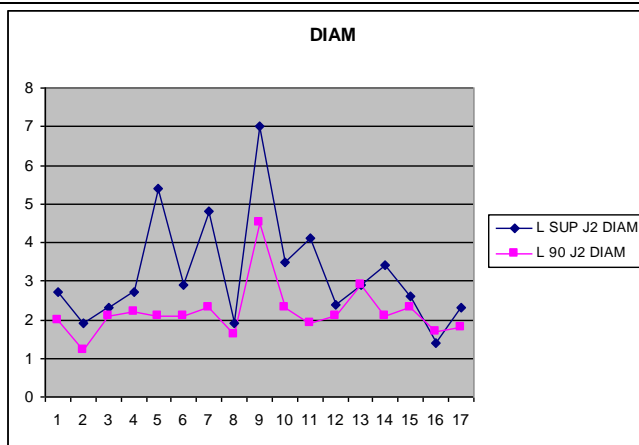
correl -0,000578201

linest -0,000258952 2,394935632



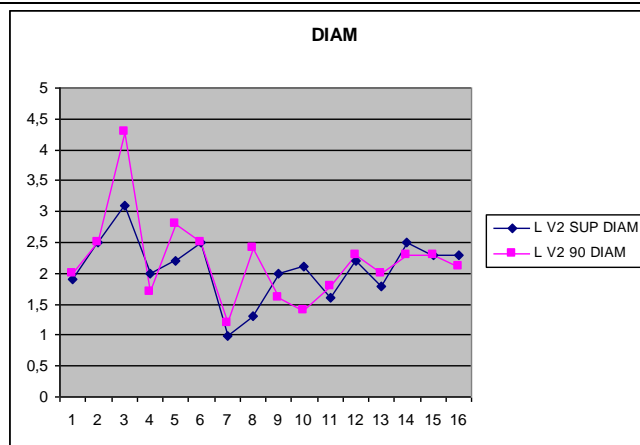
correl 0,310257954

linest 0,22176354 1,600379789



correl 0,740122939

linest 0,360504444 1,038862303



correl 0,708290163

linest 0,987590486 0,145811789

EDEMA IN T2: A POSSIBLE PRECURSOR OF SPONTANEOUS INTRACEREBRAL HEMORRHAGE IN STROKE-PRONE SPONTANEOUSLY HYPERTENSIVE RATS?

Weili Zheng, PhD¹, Yimin Shen, PhD¹, E. Mark Haacke, PhD¹ and Helen Nichol, PhD²

¹Radiology, Wayne State University, 3990 John R Road, Detroit, MI 48201 USA

²Department of Anatomy and Cell Biology, University of Saskatchewan, Saskatoon, SK, Canada

ABSTRACT:

Purpose

To find the MR imaging precursors of spontaneous intracerebral hemorrhage in stroke-prone spontaneously hypertensive rats (SHRSP) using T2 weighted imaging and susceptibility weighted imaging.

Materials and Methods

Eighteen stroke-prone spontaneous hypertensive rats (SHRSP, Charles River strain code 324) were freely fed with Ziegler Brothers Japanese Diet 522880000 (0.9% NaCl), along with 1% salt added to the water starting at 8 weeks of age. To induce strokes more quickly, in the second group, six male SHRSP rats went through the same experiment but were fed with a high-salt diet (522880000 (4% NaCl)) along with 1% salt in the water. Rats were euthanized at the first sign of obvious neurological deficit, in compliance with the regulations of institutional animal care and use committee at Wayne State University. All rats were euthanized or died spontaneously by 20 weeks of age. The brains were fixed or flash frozen.

Rats were imaged weekly (12-18 weeks) under isoflourane anesthesia (2% v/v). The T2w (TR=3.53s, TE=38ms, resolution=125x125x1000 (μm)³), T1w (3D FLASH, TR=22ms, TE=2.5ms, FA=23deg, Res=125x125x250 (μm)³), and SWI (TR=75ms, TE=5.5, ~27.4ms for some rats and TE=2.79~25.71ms for the others. FA=15°, Res=39x39x250 (μm)³) scans were performed on 7T (CLinScan; Bruker, Karlsruhe, Germany). In some animals, Gd-DTPA (0.3 mol/kg) was injected via tail vein to investigate the integrity of vasculature. SWI images were processed using SPIN (Signal Processing in NMR, Detroit, MI, USA).

Results

Of the first group of 18 rats, 6 developed stroke at 14-18 weeks of age. Three hemorrhagic lesions were located in the striatum and three located in the cortex. For the striatum lesions, edema was seen in T2 one week before the lesions were visible in SWI. These lesions were not accompanied with neurological deficits (sign of stroke) but deficits did appear one or two weeks later. However, the cortical lesions were immediately accompanied with signs of stroke. The hemorrhagic lesions were dominated with cluster of microbleeds at striatum lesions and patch of light bleeding at cortical lesions. The second group of 6 rats fed high salt in both the diet and water developed stroke at 10-13 weeks of age. Hemorrhages occurred earlier and more

frequently as has been reported in the literature (1). In addition to the cortex and striatum, hemorrhage also developed at the corpus callosum in 2 rats. For the striatum lesions, the edema in T2 was detected at least one week before it was detected in SWI with only one exception. With one exception, no edema preceded the cortical lesions as detected by SWI. Once the edema was found in T2, DCE was performed and Gd leakage from the vessels was observed within the region of edema, in agreement with the literature (1).

Table 1: Summary of the occurrence of stroke and it's time line in two groups of SHRSP rats. Cor: Cortex; Str: Striatum; CC: Corpus Callosum; Shaded areas: rats were sacrificed in that week.

Group	Rat	Week 14		Week 15		Week 16		Week 17		Week 18	
		T2 (Edema)	SWI (Microbleeds or hemorrhage)	T2	SWI	T2	SWI	T2	SWI	T2	SWI
1st	3							Cor	Cor		
	4	Str		Str	Str						
	7	Cor	Cor								
	12	Str		Str	Str	Str, Cor	Str, Cor				
	16									Str, Cor	Str, Cor
		Week 10		Week 11		Week 12		Week 13			
2nd	1			Str		Str, Cor	Str	Str, Cor	Str, Cor		
	2	Str, Cor, CC	Str, Cor, CC								
	3	Str									
	4	Str	Str	Str, Cor	Str, Cor						
	5	Str, Cor, CC	Str, Cor, CC								

Conclusion

We conclude that edema in T2 indicates that there is a breakdown of the blood brain barrier in vessels in this area and this may precede by several days a striatal spontaneous intracerebral hemorrhage in SHRSP rats. Therefore if edema is seen in T2, immediate treatment could improve outcome (2). However, cortical hemorrhages seem to differ from striatal hemorrhages in that either edema does not occur or occurs very shortly before the bleed.

Acknowledgments

This work is supported by Heart and Stroke Foundation of Canada (HSFC) and the Canadian Institutes of Health Research (CIHR) - Institute of Circulatory and Respiratory Health, Clinical Imaging Initiative (FRN - 99472) to HN.

References

(1) Lee et al. Stroke 2007, 38:3289-3291. (2) Yamori & Horie, Stroke 1977, 8:456-461.

CORRELATION OF MICROPARTICLE SPECIES IN MS WITH IRON DEPOSITION IN THE BRAIN

J Alexander Steven, BS, PhD¹, Alireza Minagar, MD², Robert Chervenak, BS, PhD³, Bianca Weinstock-Guttman, BS, MD⁴, Tsunoda Ikuo, MD, PhD³, Chaitanya Ganta Vijay, BS, PhD¹, Ramanathan Murali, PhD⁵ and Robert Zivadinov, MD, PhD⁶

¹Louisiana State University, 1501 Kings Hwy, Dept of Molecular & Cellular Physiology, Shreveport, LA USA

²Louisiana State University, 1501 Kings Hwy, Dept of Neurology, Shreveport, LA USA

³Louisiana State University, 1501 Kings Hwy, Dept of Microbiology, Shreveport, LA USA

⁴State University of New York, Buffalo, 100 High Street, Buffalo General Hospital, Buffalo, NY, Buffalo USA

⁵State University of New York, Buffalo, 355 Kapoor Hall, School of Pharmacy and Pharmaceutical Sciences, Buffalo, NY USA

⁶Buffalo Neuroimaging Analysis Center, 100 High Street, Suite E-2 Buffalo General Hospital, Buffalo, NY USA

ABSTRACT:

Multiple Sclerosis (MS) remains a progressive and disabling neurological disease which affects young adults and remains incurable. Although MS is conceived to represent an excessive and inappropriate immune response to certain putative central nervous system (CNS) autoantigens, increasing evidence also suggests that MS represents a neurovascular inflammatory disease characterized by endothelial activation and shedding into the circulation of the cell membrane microdomains known as 'microparticles'. In order to investigate the relationships between these endothelial biomarkers and MS, we examined the relative abundance of CD31⁺/PECAM-1, CD51⁺/CD61⁺ (□V□3) and CD54⁺(ICAM-1) bearing microparticles in the plasma of healthy individuals and patients with relapsing remitting multiple sclerosis (RRMS) and secondary progressive MS (SPMS). We also correlated plasma levels of different microparticle species in MS with conventional magnetic resonance (MR) imaging (T1/T2 intensity) as well as novel MR modalities (Sienax inpainting, iron signatures) to develop a relationship among these variable to objectively quantify disease activity in MS. We found that despite similar overall plasma microparticle levels among these groups, several microparticle species including CD31⁺/CD51⁺/CD61⁺/CD54⁺were statistically correlated with conventional MR imaging features of MS. Based on the results of this cross sectional study we conclude that endothelial microparticle profiles in MS may provide mechanistic evidence of microvascular stress and injury which is an underlying contributor to not only MS initiation and progression but also immune persistence.

ENDOVASCULAR TREATMENT OF ACUTE STROKE - CZECH EXPERIENCE.

Dusan Kucera

Vascular Centre, Vítkovice Hospital Ostrava, Czech Republic

Objective: a retrospective review of our experience with endovascular recanalization of intracranial arterial occlusion in patients with acute ischemic stroke.

Patients and Method: local intracranial thrombolysis was performed within 6 hours from symptom onset in anterior circulation and within 12 hours in vertebrobasilar circulation. In total, during the years 2000-2012 we treated 137 patients in whom no hypodensity areas were observed on initial CT. As a method of treatment was used either local intra-arterial thrombolysis alone or in combination with percutaneous angioplasty, or stenting accompanied with using different forms of mechanical recanalization as Merci or Catch catheter or Solitaire stent system. Methods of percutaneous recanalization were classified as direct (if used as the primary method of treatment) or as a rescue (after failed systemic thrombolysis).

Results: The technical success (artery recanalization flow with TIMI flow 3 or 2) was achieved in 72.2% of patients. If we applied percutaneous recanalization as a rescue method of treatment after unsuccessful systemic thrombolysis, we achieved a technical success of 78.8% compared to 65.6% in patients with direct power. Clinical improvement was detected in 75.6% of patients with anterior circulation and 53.3% of patients with posterior circulation. There were 11,3% of intracranial hemorrhage and 30 days mortality was 9,9%.

Conclusion: The methods of percutaneous recanalization of intracranial arterial occlusion in patients with acute stroke are, in our experience, technically feasible and safe methods of treatment of acute stroke with high efficiency of recanalization rate of arterial occlusion. The present results encourage us to perform further clinical trials in a larger number of patients to assess the clinical success of this procedure.

Quantitative Magnetic Resonance Venography in MS Patients

EM Haacke^{1,2}, PhD, D Utriainen¹, BS, S Sethi¹, MS, W Feng², PhD, JJ Hewett³, MD, M Arata³, MD

¹MR Innovations, ²Wayne State University, ³Pacific Interventionalists

Introduction: Quantitative imaging of CCSVI using magnetic resonance imaging (MRI) provides an opportunity to study not just anatomical abnormalities¹⁻⁸ but also the ability to quantify flow^{2,3,4,7,9}. These two pieces of information may provide new biomarkers over and above those originally introduced by Zamboni⁸ et al using ultrasound. Specifically, recent MRI findings suggest that the total internal jugular vein (IJV) flow normalized to the total arterial inflow as measured from the carotids and vertebral arteries and the dominance of flow on one side of the neck may represent risk factors for developing MS²⁻⁴.

Materials and Methods: A previous study of 323 MS subjects was compared with a new group of 145 MS subjects and 33 healthy controls. IJV structure was assessed for stenosis, atresia, and aplasia using a combination of 2D time of flight MR venography (TOF MRV) and 3D contrast enhanced MR angiography and venography (CE MRV). The subjects were sub-grouped into stenotic (ST) and non-stenotic (NST) categories. Two dimensional phase contrast flow quantification (PC FQ) was used to quantify the flow through the vessels of the neck perpendicular to the IJV positioned between the sixth and seventh cervical vertebrae as well as the second and third cervical vertebrae. All data were processed using FlowQ (for flow quantification) and SPIN (signal processing in NMR, for anatomical assessment) software. IJV flow was normalized to the total arterial input. All data were collected on a Siemens 3T TRIO scanner.

Results: For the 145 MS patients, 71 were categorized as NST and 74 as ST. IJV flow was normalized to arterial flow and plotted as C2 vs C6. A total of 22 (28.4%) of the ST MS, 1 (1.4%) of the NST MS, and 1 (3.0%) of the healthy controls fell below 50% at both levels. This agreed with our previous findings in which none of the 100 NST MS patients fell below 50% at both levels while 70 (31.4%) of the ST MS did.

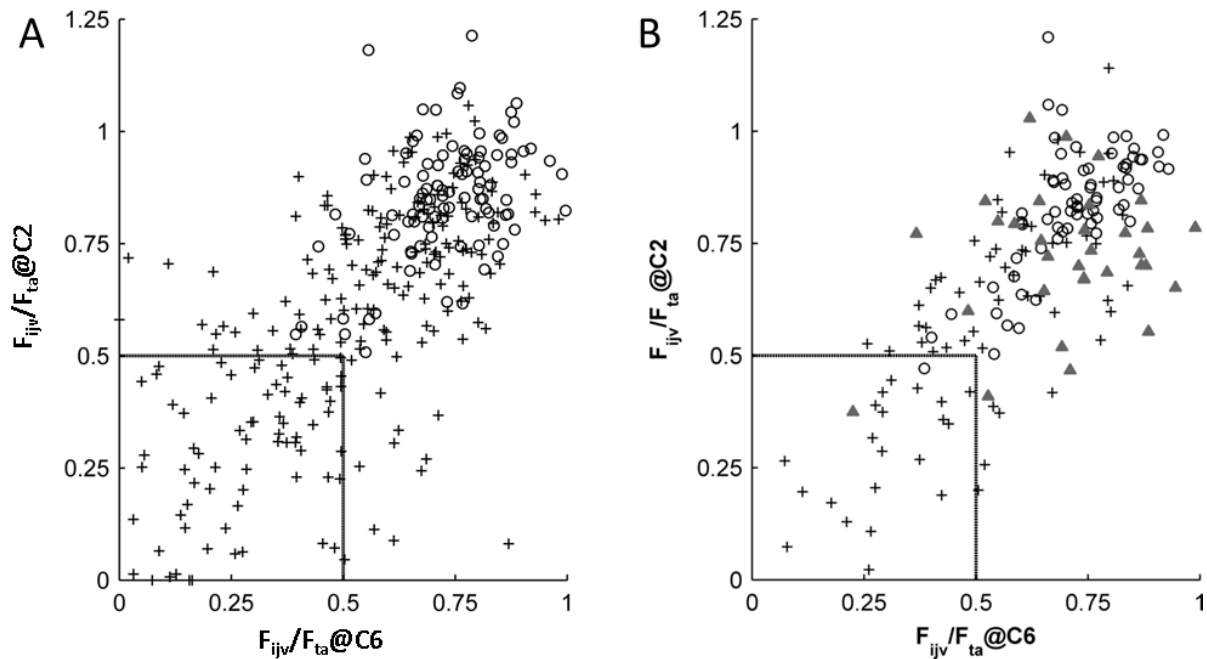


Figure 1: Plots showing the total IJV flow (F_{ijv}) normalized to the total arterial flow (F_{ta}) at the C2 level vs. the C6 level for two separate samples. Legend: triangle=healthy control, open circle=NST MS, cross=ST MS. (A) Published data on 323 MS subjects, 223 ST and 100 NST². (B) A new group of 145 MS, 74 ST and 71 NST, and 33 healthy controls.

Discussion and Conclusion: Quantifying flow for studying CCSVI in MS is a critical part of evaluating what is abnormal in an MS patient. It is now clear that a significantly higher portion of the MS population shows low internal jugular vein flow compared to normal controls and that 2D PCFQ serves as a key biomarker for MS.

References: 1) F. Doepp et al, *Neur.* 2011; 77: 1745. 2) W. Feng et al., *Radiological Research*, 34:8, 802-809, 2012. 3) W. Feng et al, *Rev Recent Clin Trials* 2012; 7: 117-126. 4) EM Haacke et al. *JVIR* 2012; 23: 60-68 e61-63. 5) D. Hojnacki et al, *Int Angiol* 2010; 29: 127-139. 6) P Sundstrom et al, *Ann Neurol* 2010; 68: 255-259. 7) D Utriainen et al, *Tech Vasc Interv Radiol* 2012; 15: 101-112. 8) P Zamboni et al, *Eur J Vasc Endovasc Surg* 2012; 43: 116-122. 9) T Ludyga et al. *Phlebology* 2010; 25: 286-295. 10) JH Simon JH et al, *AJNR* 2006; 27: 455-461.

Post-inflammatory white Matter and Deep Gray Matter Hemodynamic Changes in Multiple Sclerosis Patients with Clinically Isolated Syndrome and correlation with memory function

Multiple sclerosis (MS) is a common autoimmune disorder of the Central Nervous System (CNS) characterized by inflammatory demyelination and secondary axonal degeneration. Most patients with MS initially present with an isolated neurological deficit of acute or subacute onset, called "clinically isolated syndrome" (CIS) [1]. Longitudinal studies have shown that the majority of these patients will subsequently experience additional relapses, thus converting to clinically definite MS.

Due to its high sensitivity in identifying free water within the normally myelinated white matter, MRI has become the ideal imaging modality for the detection of cerebral white matter diseases and an essential tool for the early diagnosis of MS and its distinction from other clinical entities [2, 3]. Moreover, the advent and application of advanced MRI techniques further increased its ability to depict microscopic changes, otherwise occult by conventional MRI [4].

Previous neuropathological studies, showing that perivascular inflammatory changes and hyalinization occur in vein walls in normal appearing white matter (NAWM) of patients with MS [5,6], have raised the possibility that a subacute or chronic vasculitis may underlie MS. This possibility, may be relevant to observations that MS plaques typically develop along venous structures forming the so called "Dawson's fingers. Lucchinetti et al [7], also, recently described that extensive brain inflammation represents the initial histologic change in MS. Angiogenesis in MS has been, also, supported by studies showing increased blood vessel density and endothelial cell proliferation, along with increased vascular endothelial growth factor expression [8,9].

It is thus possible that vascular changes occurring in MS could lead to altered cerebral hemodynamics that can be assessed with the use of dynamic susceptibility contrast-enhanced (DSC) T2*-weighted (w) MRI [10]. There is a limited number of studies employing DSC-MRI in patients with clinically definite MS, revealing diffuse hemodynamic impairment both in NAWM and in normal appearing deep gray matter [NADGM] areas [11-15]. These findings were thought to reflect primary vascular pathology rather than decreased metabolic demand. On the other hand, increased perfusion has been found in acute enhancing and in some chronic reactivated non-enhancing MS plaques, indicating that DSC-MRI is sensitive in detecting inflammatory activity in acute phases of the disease [12].

Memory disturbances are known to occur in early MS [16-18], but brain morphological changes, as detected by conventional MRI techniques, cannot adequately explain this cognitive impairment [19, 20].

We hypothesized that hemodynamic alterations occur not only at the stage of clinically definite MS, but also in CIS. As multiple cerebral regions are known to be operational during mental processes, such as memory, we also tested the hypothesis whether memory changes relate to hemodynamic disturbances of specific brain structures. For this we applied the DSC-MRI technique and obtained detailed

cognitive evaluations in 30 patients with CIS and 30 relapsing-remitting MS (RRMS) patients, while 30 normal volunteers (NRM) were used as controls.

MR Imaging

All patients and normal controls underwent brain MRI on a 1.5 T whole-body scanner. The protocol for MS was applied and the T2* DSC-MRI was performed utilizing a 2D single shot multi slice Gradient Echo Echo Planar Imaging (GREEPI) sequence. Twenty 4 mm consecutive slices were obtained in an oblique axial plane covering the whole brain. The sequence was repeated every 1.5 s, thus obtaining 50 dynamic acquisitions (images) for each of the 20 anatomical slices. Immediately after the end of the fifth dynamic acquisition, a bolus of 0.1 mmol/kg body weight of gadobutrol was injected through a catheter inserted in the antecubital vein, at an injection rate of 4 mL/s, immediately followed by a bolus injection of 15 ml of saline at the same rate.

Image Processing and Evaluation

Post-processing of the perfusion data was performed utilizing standard software provided by the manufacturer. The DSC-MRI perfusion technique was based on a standard tracer kinetic model with arterial input function calculation [23-25] and a deconvolution method based on a singular value decomposition algorithm [26-27]. The arterial input function was calculated by manually defining a major artery (usually the MCA) and parametric maps of cerebral blood volume (CBV), cerebral blood flow (CBF), and mean transit time (MTT) values were automatically created. CBV, CBF, and MTT values were calculated in 20 regions of interest (ROIs) located at the periventricular white matter, semioval center, subcortical white matter (in the frontal, parietal, temporal and occipital lobes), thalami, putamen and caudate nuclei, bilaterally, and also at the splenium and genu of the corpus callosum (CC).

RESULTS

As compared to CIS, the RR-MS group had longer disease duration (6.9 ± 4.6 ; CIS: 1.5 ± 1.5 years) and a higher degree of disability (EDSS= 1.5 ± 1.1 ; CIS: 1.0 ± 0.5).

Active MS lesions (Gadolinium- enhancing) were found in six of the 30 CIS patients and in four of the 30 RRMS patients studied.

Compared to the control group, both CIS and RR-MS patients had significantly impaired age- and education-adjusted scores on verbal working memory (Memory for Digits Reverse).

Comparison of the regional perfusion metrics between CIS Patients and controls

Patients with CIS showed significantly elevated CBV and MTT values than controls ($P < 0.001$) across all 20 ROIs studied. Similarly, the CBV and MTT values of the average white matter (AVWM) and average deep gray matter (AVDGM) were significantly higher ($P < 0.001$) in patients with CIS than in controls. Conversely, patients with CIS showed significant decreases in the CBF values of the thalami, the

caudate nuclei, and of the AVDGM, compared to controls. There was only a slight tendency for reduced CBF in the rest of ROIs.

Comparison of the regional perfusion metrics between patients with RRMS and controls

Significantly lower CBF values were found in all of the measured NAWM and NADGM areas ($P < 0.001$) between RRMS and controls. In addition, the AVWM and AVDGM CBF values were decreased significantly in patients with RRMS as compared to controls. In contrast, the corresponding CBV and MTT values were comparable between the two groups although a trend for decreased CBV values was detected. When patients with CIS were compared to those with RR-MS, the former showed significantly higher CBV and MTT values across all ROIs.

Associations between brain perfusion and memory measures

In CIS patients, negative correlations were found between CBV and verbal memory indices, with Digits Reverse correlating inversely with CBV values of the left frontal NAWM, the genu and the splenium of the CC. Immediate and delayed free recall scores also correlated inversely with CBV values in left frontal NAWM, and in the right thalamus and caudate.

DISCUSSION

This study showed that the NAWM and NADGM of patients with CIS are characterized by increased CBV and MTT values as compared to controls and patients with RRMS. It was, also, shown, that significantly impaired scores on verbal working memory and secondary verbal memory in CIS patients correlated inversely with elevated CBV of brain regions thought to be involved in memory function. Although the mechanism(s) responsible for the globally increased CBV values in patients with CIS demonstrated here is currently unclear, inflammation-induced vasodilatations, afflicting both the NAWM and NADGM at the very early stages of MS, may be operating. These inflammation-related processes, may disrupt crucial interhemispheric connections and connections with left frontal lobe cortical regions, affecting working memory.

Increased regional perfusion is shown to occur several weeks prior to contrast enhancement of MS lesions [28]. As such, the increased CBV values at the NAWM and NADGM regions without concomitant Gd-enhancement of patients with CIS, observed here, could reflect inflammation (before the local blood–brain barrier breakdown) that remains undetectable by conventional post-contrast MRI.

New vessel formation, along with increased vascular endothelial growth factor expression, have been shown early in the development of MS lesions [8,9]. CBV has been proved to be a sensitive marker of angiogenesis, with significant correlations having been reported between the increase of relative CBV and histologically determined microvessel density [29]. It is possible that the elevated CBV values in both the NAWM and NADGM of the patients with CIS may be indicative of angiogenesis that occurs in addition to post-inflammatory vasodilatations of the existing vessels at the earliest stages of MS.

The CBF values of the caudate, thalamus, and the AVDGM in patients with CIS were significantly lower as compared to controls. Similarly, there was a trend for the CBF values of the NAWM to be lower in the patients with CIS than in controls, but these differences were not significant. The immature new vessels in MS show increased vascular permeability [30], leading to edema that might cause focal disturbance of the local microcirculation with subsequent ischemia [31]. This could account for the decreased CBF values found in patients with CIS, particularly at the DGM tissues which are more vulnerable to ischemia.

The present data, showing that RRMS patients exhibit significantly lower CBF values in the NAWM and NADGM, as compared to controls, are in agreement with previous nuclear medicine [32] and DSC-MRI investigations [11–15]. The globally decreased perfusion in MS is thought to result from diffuse perivascular inflammation, leading to microvessel damage, thrombosis, and fibrin deposition, as proved by histopathologic studies [6]. These observations have raised the possibility for a primary vascular etiology for MS.

According to our findings, patients with CIS demonstrated significantly increased CBV, CBF, and MTT values as compared to patients with RRMS in almost all the measured NADGM and NAWM areas. It is thus possible that post-inflammatory vasodilation and angiogenesis occur at the earliest stages of MS, preceding the vascular damage and the consequent hemodynamic impairment seen in patients with RRMS.

Memory performance in CIS correlated inversely with CBV values for several brain structures thought to be involved in memory function. These included the left frontal normal appearing white matter, right thalamus, right caudate and corpus callosum. Since elevations in CBV and MTT are consistent with tissue inflammation and/or angiogenesis, the cognitive deficits in early MS may relate to widespread brain inflammatory processes that prevail at this disease stage.

CONCLUSIONS

In summary, this study detected increased CBV values in all regions of the NAWM and of the NADGM evaluated in patients with CIS, as compared to patients with RRMS and to NRM controls. These could have resulted from diffuse inflammation-mediated vasodilatation or even angiogenesis at the earliest stage of MS. Cognitive deficits in CIS patients correlated inversely with elevated CBV of brain regions thought to be involved in memory function. These observations suggest that inflammation-related processes, which represent the initial neuropathologic change of MS, may affect working memory.

REFERENCES

1. Miller D, Barkhof F, Montalban X, Thompson A, Filippi M. Clinically isolated syndromes suggestive of multiple sclerosis, part 1: natural history, pathogenesis, diagnosis, and prognosis. *Lancet Neurol* 2005;4:281–288.
2. Rot U, Mesec A. Clinical, MRI, CSF and electrophysiological findings in different stages of multiple sclerosis. *Clin Neurol Neurosurg* 2006; 108:271–274.

3. Miller DH, Weinshenker BG, Filippi M, et al. Banwell BL, Cohen JA, Freedman MS, Galetta SL, Hutchinson M, Johnson RT, Kappos L, Kira J, Lublin FD, McFarland HF, Montalban X, Panitch H, Richert JR, Reingold SC, Polman CH. Differential diagnosis of suspected multiple sclerosis: a consensus approach. *Mult Scler* 2008;14:1157–1174.
4. Bakshi R, Thompson AJ, Rocca MA, et al. MRI in multiple sclerosis: current status and future prospects. *Lancet Neurol* 2008;7:615–625.
5. Adams CW, Poston RN, Buk SJ, et al. Inflammatory vasculitis in multiple sclerosis. *J Neurol Sci* 1985;69:269–283.
6. Wakefield AJ, More LJ, Difford J, McLaughlin JE. Immunohistochemical study of vascular injury in acute multiple sclerosis. *J Clin Pathol* 1994;47:129–133.
7. Lucchinetti CF, Popescu BF, Bunyan RF, et al. Inflammatory cortical demyelination in early multiple sclerosis. *N Engl J Med* 2011; 365: 2188–2197
8. Holley JE, Newcombe J, Whatmore JL, Gutowski NS. Increased blood vessel density and endothelial cell proliferation in multiple sclerosis cerebral white matter. *Neurosci Lett* 2010;470:65–70.
9. Roscoe WA, Welsh ME, Carter DE, Karlik SJ. VEGF and angiogenesis in acute and chronic MOG (35–55) peptide induced EAE. *J Neuroimmunol* 2009;209:6–15.
10. Zaharchuk G. Theoretical basis of hemodynamic MR imaging techniques to measure cerebral blood volume, cerebral blood flow, and permeability. *AJNR Am J Neuroradiol* 2007;28:1850–1858.
11. Law M, Saindane AM, Ge Y, et al. Microvascular abnormality in relapsing-remitting multiple sclerosis: perfusion MR imaging findings in normal-appearing white matter. *Radiology* 2004;231:645–652.
12. Ge Y, Law M, Johnson G, Babb JS, Mannon LJ, Grossman RI. Dynamic susceptibility contrast perfusion MR imaging of multiple sclerosis lesions: characterizing hemodynamic impairment and inflammatory activity. *AJNR Am J Neuroradiol* 2005;26:1539–1547.
13. Adhya S, Johnson G, Herbert J, et al. Pattern of hemodynamic impairment in multiple sclerosis: dynamic susceptibility contrast perfusion MR imaging at 3.0 T. *Neuroimage* 2006;33:1029–1035.
14. Inglese M, Park S-J, Johnson G, et al. Deep gray matter perfusion in multiple sclerosis dynamic susceptibility contrast perfusion magnetic resonance imaging at 3 T. *Arch Neurol* 2007;64:196–202.
15. Saindane AM, Law M, Ge Y, Johnson G, Babb JS, Grossman RI. Correlation of diffusion tensor and dynamic perfusion MR imaging metrics in normal-appearing corpus callosum: support for primary hypoperfusion in Multiple Sclerosis. *Am J Neuroradiol*. 2007; 28:767–772.
16. Feillet L, Reuter F, Audoin B, et al. Early cognitive impairment in patients with clinically isolated syndrome suggestive of multiple sclerosis. *Mult Scler* 2007 ; 13: 124–127.
17. Panou T, Mastorodemos V, Papadaki E, Simos P, Plaitakis A. Early signs of memory impairment among multiple sclerosis patients with clinically isolated syndrome. *Behav Neurol* 2012; 25: 311–326.

18. Glanz BI, Holland CM, Gauthier SA, et al. Cognitive dysfunction in patients with clinically isolated syndromes or newly diagnosed multiple sclerosis. *Mult Scler* 2007; 13: 1004-1010.
19. Benedict RH, Weinstock-Guttman B, Fishman I, Sharma J, Tjoa CW, Bakshi R. Prediction of neuropsychological impairment in multiple sclerosis: comparison of conventional magnetic resonance imaging measures of atrophy and lesion burden. *Arch Neurol* 2004; 61:226-230.
20. Christodoulou C, Krupp LB, Liang Z, et al. Cognitive performance and MR markers of cerebral injury in cognitively impaired MS patients. *Neurology* 2003; 60:1793-1798.
21. Mastorodemos V, Nikolakaki H, Tzagournissakis M, et al. Benign multiple sclerosis in Crete. *Mult Scler* 2010; 16: 701-706.
22. Polman CH, Reingold SC, Banwell B, et al. Diagnostic criteria for multiple sclerosis: 2010 Revisions to the McDonald criteria. *Ann Neurol* 2011; 69:292-302.
23. Tofts PS. Modeling tracer kinetics in dynamic Gd-DTPA MR imaging. *J Magn Reson Imaging* 1997;7:91-101.
24. Ostergaard L, Weisskoff RM, Chesler DA, Gyldensted C, Rosen BR. High resolution measurement of cerebral blood flow using intravascular tracer bolus passages, part 1: mathematical approach and statistical analysis. *Magn Reson Med* 1996;36:715-725.
25. Ostergaard L, Sorensen AG, Kwong KK, Weisskoff RM, Gyldensted NC, Rosen BR. High resolution measurement of cerebral blood flow using intravascular tracer bolus passages, part 2: experimental comparison and preliminary results. *Magn Reson Med* 1996;36:726-736.
26. Calamante F, Gadian DG, Connelly A. Delay and dispersion effects in dynamic susceptibility contrast MRI: simulations using singular value decomposition. *Magn Reson Med* 2000;44:466-473.
27. Wirestam R, Andersson L, Ostergaard L, et al. Assessment of regional cerebral blood flow by dynamic susceptibility contrast MR using different deconvolution techniques. *Magn Reson Med* 2000;13:691-700.
28. Wuerfel J, Bellmann-Strobl J, Brunecker P, et al. Changes in cerebral perfusion precede plaque formation in multiple sclerosis: a longitudinal perfusion MRI study. *Brain* 2004;127:111-119.
29. Pathak AP, Schmainda KM, Ward BD, et al. MR-derived cerebral blood volume maps: issues regarding histological validation and assessment of tumor angiogenesis. *Magn Reson Med* 2001;46:735-747.
30. Plumb J, McQuaid S, Mirakhur M, Kirk J. Abnormal endothelial tight junctions in active lesions and normal-appearing white matter in multiple sclerosis. *Brain Pathol* 2002;12:154-169.
31. Lassmann H. Hypoxia-like tissue injury as a component of multiple sclerosis lesions. *J Neurol Sci* 2003;206:187-191.
32. Sun X, Tanaka M, Kondo S, Okamoto K, Hirai S. Clinical significance of reduced cerebral metabolism in multiple sclerosis: a combined PET and MRI study. *Ann Nucl Med* 1998;12:89-94.

Marian Simka

Affiliation: Euromedic Medical Center, Department of Vascular Surgery, Katowice, Poland

How reliable are current sonographic CCSVI criteria?

Introduction. Chronic cerebrospinal venous insufficiency is characterised by stenoses of extracranial and extraspinal veins draining the brain and spinal cord, primarily the internal jugular veins and the azygous vein, associated with opening of collateral outflow routes and insufficient cerebral venous drainage. A prospective study was aimed at evaluation of diagnostic value of Doppler sonography for the assessment of such abnormalities in the internal jugular veins. Also, such a diagnostic accuracy was calculated for T2 FatSat and TOF MR imaging.

Methods. There were assessed 252 internal jugular veins in 126 patients with associated multiple sclerosis. Findings of Doppler sonography and MR venography were compared to the results of reference test: catheter venography. We evaluated our findings in the context of current sonographic criteria, proposed by *Zamboni*, and the new criteria by expert panel of the *International Society for Neurovascular Disease (ISNVD)*.

Results. Positive and negative Bayesian likelihood ratios for at least 1 and 2 Zamboni's criteria and at least 1 and 2 ISNVD criteria were: 69.0%/43.4%, 73.9%/34.1%, 68.8%/40.2%, 73.9%/36.4%, respectively and for T2 FatSat, TOF and T2 FatSat + TOF MR imaging positive and negative Bayesian likelihood ratios were: 75.8%/72.1%, 77.1%/66.8% and 75.2%/70.9%, respectively.

Conclusion. Our research has shown that currently used sonographic criteria for the detection of obstructive venous abnormalities in the internal jugular veins are of limited diagnostic value. It seems that the main cause of poor accuracy of current sonographic criteria is the lack of precise definition of an abnormality.

Using systems analysis to investigate the root causes of multiple sclerosis, developing an integrated treatment strategy

Harald U. Sverdrup¹, Kristín Vala Ragnarsdóttir², Thomas Ragnar Wood³, Ulrik Sverdrup⁴

¹ Chemical Engineering, Lund University, Box 124, SE-221 00 Lund, Sweden

² Earth Sciences, University of Iceland, 101 IS-Reykjavik, Iceland

³ Guy's and St Thomas' Hospital, Great Maze Pond, London SE1 9RT, Great Britain

⁴ Physics Engineering Programme, LTH, Lund University, SE-221 00 Lund, Sweden

Abstract

We have been able to show that multiple sclerosis is a systemic illness with multiple interacting causes and mechanisms, by applying the methods of systems analysis to the problem. The results were obtained by synthesizing state-of-the-art research into a whole systemic picture. Some main components make up the illness system:

1. The root cause: Permeable blood-brain barrier (BBB) and transmission of provocative substances, antibodies and leucocytes into the brain, caused by:
 - a. Chronic cerebro-spinal vascular insufficiency (CCSVI), caused by valve malfunction, venous stenosis and venous blockage, causing reductions in blood flow through the brain and stagnant flow in capillaries, leading to microclotting and puncturing of the BBB
 - b. Venous inflammation, and stimulus of MMP by Interleukin 1b, leading to BBB permeability
 - c. Histamine overload, leading to BBB permeability
2. Triggers:
 - a. Antibodies to myelin and oligodendrocytes from
 - i. infections of certain bacteria and viruses;
 - ii. allergic attacks
 - iii. myelin and oligodendrocyte debris in the blood stream and the cerebro-spinal fluid
 - iv. Food particles leaking into the blood, most important are gluten and proteins from dairy products
3. Reinforcing loops:
 - a. Feedback system involving iron in the autocatalytic Fenton cycle and production of oxidants and free reactive radicals, prominently peroxynitrite, reinforcing the increased permeability of the BBB; keeping the BBB compromised
 - b. Immune response feedback loop involving immune system and myelin sheath breakdown, leading to brain side damages to the BBB, driven by oxidative denaturalization of the myelin surfaces.
 - c. Oxidant stresses, leading to scarring at damaged sites and impairment of the ability to repair myelin sheaths, making the physical damage permanent

The different causal mechanisms were linked together into one integrated model. Our analysis shows that multiple sclerosis has no single cause, it is a system of causes that in a feedback system produces multiple sclerosis as output. Qualitatively, the model is capable of describing the untreated progress of the illness as it has been observed in patients. Multiple sclerosis is contracted by a combination of several factors; an opening of the blood-brain-barrier under a prolonged period of time, provocative substances available in the blood to initiate a vicious cycle of oxidative stresses and an immune attack, set in three nested reinforcing loops. The conceptual model was used to investigate the dynamics of the illness and understand its initiation and subsequent illness progression. With the model we analyse how treatment and a cure for multiple sclerosis must be approached in a multi-disciplinary way in order to be successful. The conceptual model was further developed into a dynamic simulation model in the STELLA environment based on an interlinked differential equation system. The simulation model is capable of reconstructing the basic outline of the illness, the onset at 20-30 years of age, the transition to primary progressive at 45-55 years of age. This seems to confirm the validity of the fundamental features of our model.

COMPARISON BETWEEN CONTRAST ENHANCED MRI ANGIOGRAPHY (CE-MRA) AND DIGITAL SUBTRACTION XRAY ANGIOGRAPHY (DSA)

Siamak Salari Sharif, PhD¹, E. Mark Haacke, PhD¹, J. Joseph Hewett, MD² and Michael Arata, MD²

¹Magnetic Resonance Innovations Inc., 440 E. Ferry St, Detroit, MI 48202 USA

²Synergy Health Concepts, 4501 Birch St., Newport Beach, CA 92660 USA

ABSTRACT:

Introduction

Digital subtraction angiography (DSA) is currently the gold standard in detecting venous abnormalities in patients. The downside of this method is that it is invasive, and patients are exposed to ionizing radiation and iodinated contrast agents.. Contrast Enhanced MR Angiography (CE-MRA) is a substitute method that does not suffer from the aforementioned drawbacks. Recent studies have shown excellent correspondence between MR angiography and DSAⁱ. However in recent years there has been substantial focus on the role of venous insufficiencies in neurological diseases^{ii,iii}. In this study, we compared the results obtained from patients treated with cervical venous angioplasty using both CE-MRV and DSA to investigate if CE-MRV can be used as a pre-treatment planning^{iv,v} to study the vasculature and if it is faithful in visualizing venous abnormalities in the diagnosis of cervical venous abnormalities^{vi}.

Materials and Methods

For this study, 20 patients (8 m and 12 f, average age 45 yrs, S.D: 10 yrs) suffering from MS were recruited and imaged at Synergy Health Concepts. All patients signed a consent form for this IRB approved study. Patients included in this study are those who had previously consented to cervical venography and venous angioplasty. Patients agreed to CE-MRA under the auspices of an imaging only study conducted distinctly from the intervention. In order to perform the diagnosis, each patient underwent a series of MRI protocols which consisted of a contrast enhanced MRA using time resolved interleaved scanning with stochastic trajectories "TWIST" (Siemens 3D TRIO scanner). Here, 5 to 10cc of contrast agent (Magnevist, Bayer) was injected at a rate of 1 ml/ sec using a power injector followed by a saline flush. One 3D scan was collected every 6 seconds with imaging parameters: TR: 2.96ms, TE: 1.12ms, FA: 18deg. Matrix size: 384×288× 96 with isotropic voxel size of 0.9 mm. To assist in later registration, a set of six fiducial markers was placed in the back of the neck. An in-house image processing software (SPIN-Flow) was used to extract the vessels semi-automatically and co-register them with the X-ray data. We used a two step co-registration process; registration by means of fiducial markers for initial registration and then a detailed registration using mutual information. Once the vessels were extracted and registered with the DSA images, we measured the diameter of the vessel in both the DSA and the 2D maximum intensity projections (MIP) of the co-

registered CE-MRA data. We calculated the correlation coefficient between the vessel widths in the DSA and the MIPed images. In addition we calculated the Summed Intensity Projections (SIP) of the extracted vessels in the CE-MRA and compared them to the DSA images.

Results

Figure 1 (left) shows the comparison of CSW (cross sectional width) for the X-ray and MRA MIP. Figure 1 (right) shows the average intensity for the DSA and the SIP-MRI. It can be seen that there is good correspondence between the image intensities as well as the CSW. We found the average correlation for CSW to be 85% and 80% for three cases (this value will be updated upon processing more patients). Figure 2 shows the MIP for the X-ray (middle) and the corresponding SIP and MIP MRI images (left and right resp.). Again it can be seen that the image intensities correlate very well qualitatively.

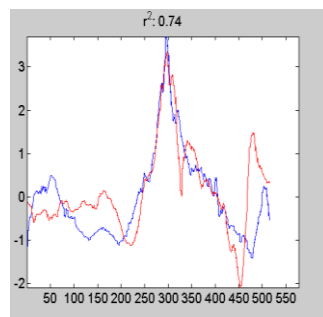
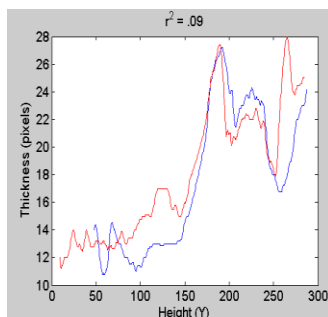


Figure 1: Left: CSW from the X-ray and SIP-MRI data of one patient. Right: Average intensity of the X-ray and SIP-MRI for the same data. (XRay: blue, SIP: red).

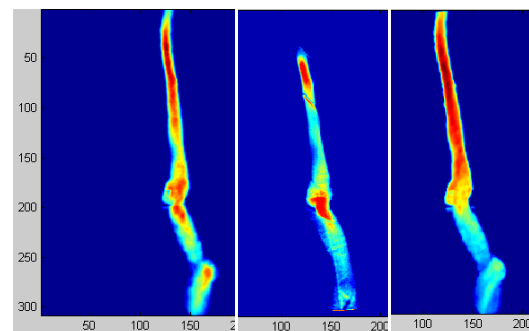


Figure 2: Left: SIP-MRI image. Middle: DSA image. Right: MIP-MRI image. It can be seen that there is very good correspondence between image intensities between SIP-MRI and DSA. The correspondence between DSA and MIP is not as good.

Conclusion

We found when the MRI images are co-registered to the DSA data, there is a very good correspondence between them. CE-MRA can accurately measure the width, as well as the cross sectional area of the vessel, which is not available through DSA. If the CE-MRA data is processed to isolate and extract the vessels, a SIP projection can provide an excellent representation of the vessel cross sectional area corresponding to the CSW of the DSA data. We conclude that the SIP projection is better than the MIP projection for a visual comparison to DSA. However it should be noted that SIP projections can only produce reliable images if the vessels are properly extracted and isolated from the surrounding tissue and converging veins. The SIP and DSA data will not always match however, since in DSA imaging the contrast is directly injected into the flow stream of the vessel and the intensity of the image is now a function of both the flow properties and diameter of the vessel. In the CE-MRA data, the intensity of the image can also depend on the flow but is integrated over 6 seconds and after time becomes rather homogeneously distributed. In our observations, we found that DSA is better at visualizing the flow at

the confluence of the internal jugular veins and the subclavian vein. In the MRV, the longer time of scanning often leads to a filling in of the contrast and we lose the real time nature available in the DSA data. On occasion though, a similar jetting through the valve can also be seen in the MRA data. In conclusion, collecting 3D CE-MRAV data can serve as a clear guide for the interventional radiologist in treatment planning for cervical venous angioplasty.

ⁱ Anzalone, N., et al. " *Radiology* 236, no. 1 (July 2005): 204–213.

ⁱⁱ Haacke, E M, et al. " *Reviews on Recent Clinical Trials* 7, no. 2 (May 2012): 100–116.

ⁱⁱⁱ Zamboni, P, et al. *Journal of Neurology, Neurosurgery & Psychiatry* 80, no. 4 (April 1, 2009): 392–399.

^{iv} Utriainen, D, et al., *Techniques in Vascular and Interventional Radiology* 15, no. 2 (June 2012): 101–112.

^v Utriainen, D, et al. *Neurological Research* 34, no. 8 (October 2012): 780–792.

^{vi} Dake, M D, *Functional Neurology* 26, no. 4 (December 2011): 181–195.